

Congenital Colorectal Conditions: Care of the Pediatric Surgical Patient

Hira Ahmad, MD

Pediatric General, Thoracic and Colorectal Surgeon

CHOC Colorectal and Urogenital Center

Rady Children's Health

<https://choc.org/general-surgery/colorectal-urogenital-program/>



Disclosures

- Lots of pictures

Objectives

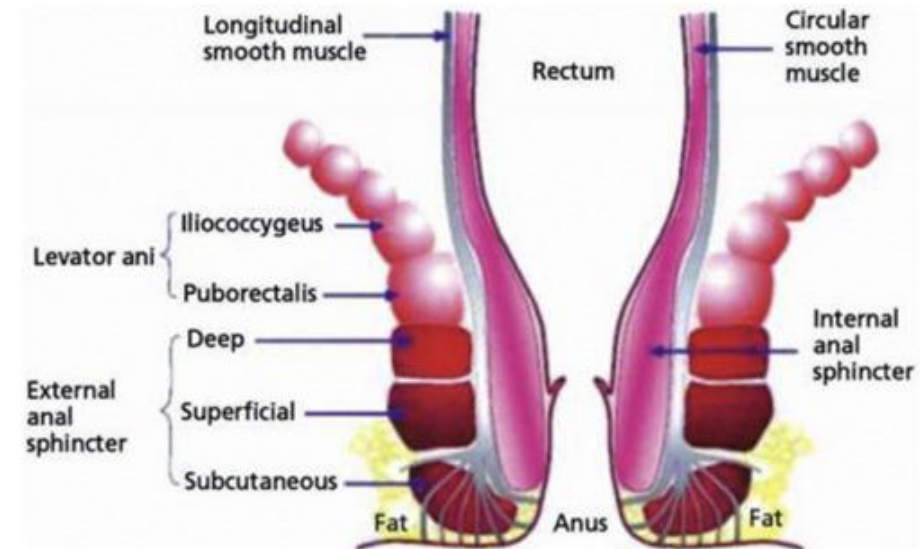
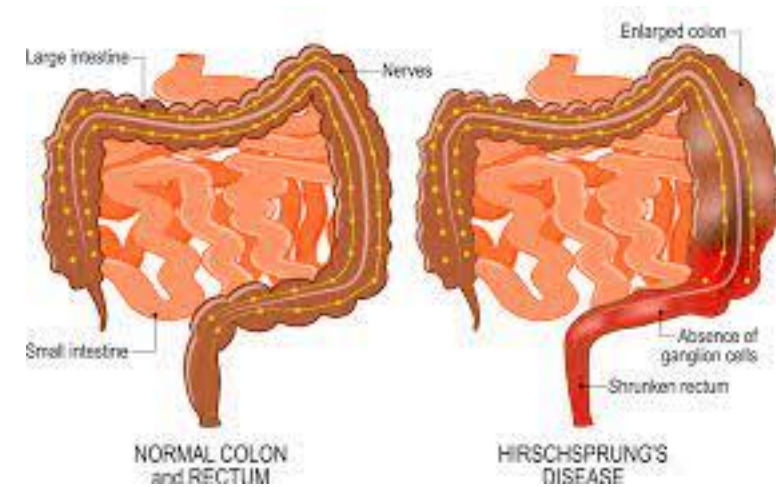
- Understand fundamental differences between:
 - Hirschsprung Disease - HD
 - Anorectal Malformations - ARM (Imperforate Anus - IA)
- Understand the purpose of the bowel prep
- Know the steps in the surgical management of ARM and HD

Agenda

- Hirschsprung Disease (HD)
- Newborn Bowel Prep
- Anorectal malformations (ARM)
 - Renal risks
- Postoperative Care
- A word about fecal incontinence

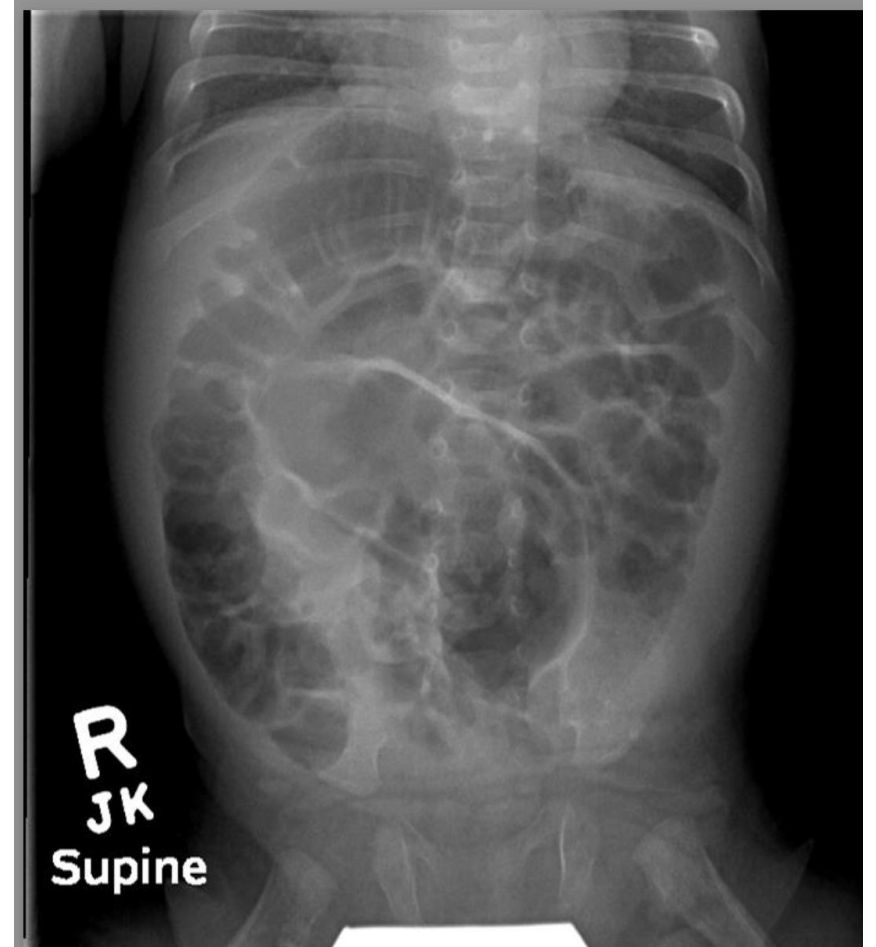
Hirschsprung Disease Characteristics

- How I describe it: no nerves = spasm
- Severity is determined by where the ganglion cells start, aka "the transition zone":
 - Males: 80% rectosigmoid, Females: 50% rectosigmoid
- Internal anal sphincters are hypertrophic, if not injured by the surgery
- 80/20 rule: 20% will suffer from enterocolitis, even if surgery is perfect
 - Can cause fatal sepsis
 - Incidence decrease with age
 - Prevented with postop irrigations



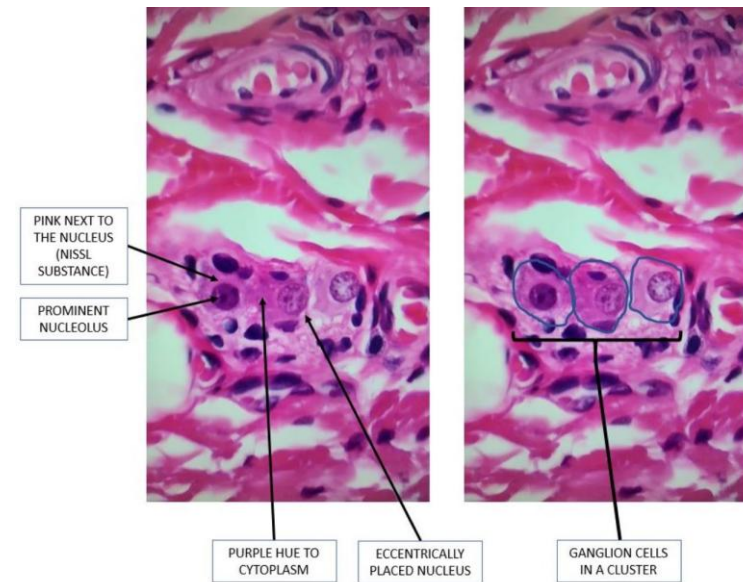
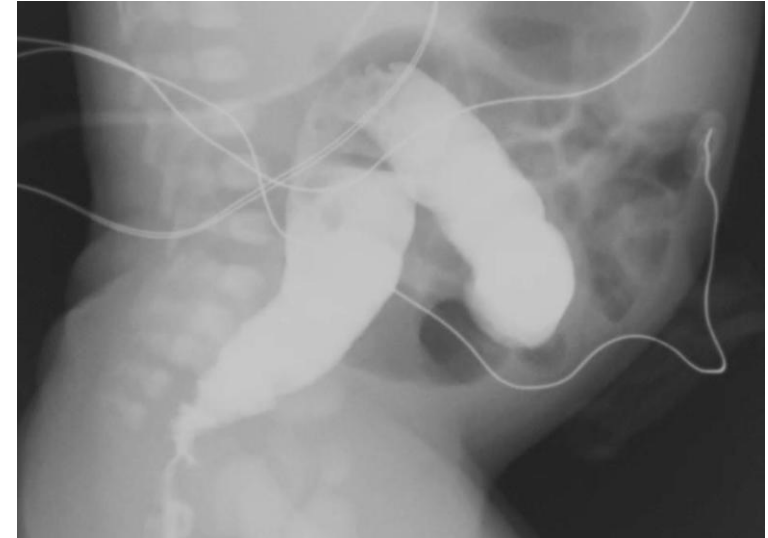Hirschsprung's Disease signs and symptoms

- Feeding intolerance → bilious emesis
- Abdominal distension
- Stooling pattern is variable
 - Increase suspicion in patients with failure to pass meconium within 48 hours
- *Signs of sepsis = Enterocolitis*



Hirschsprung's Disease: Diagnosis

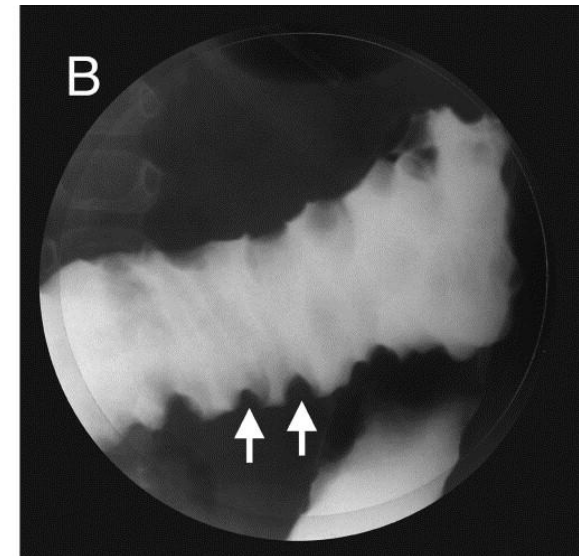
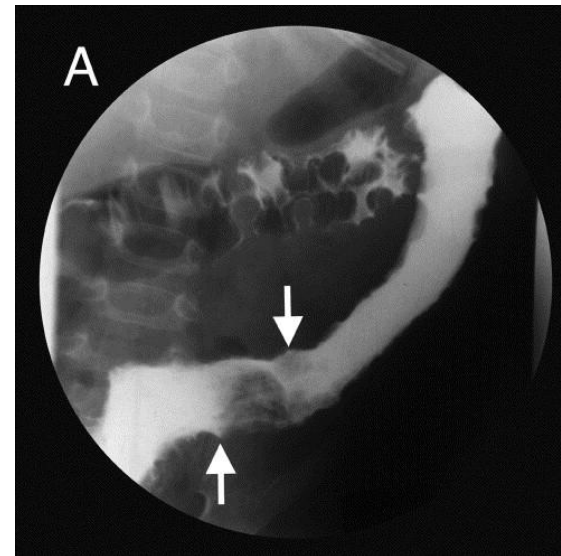
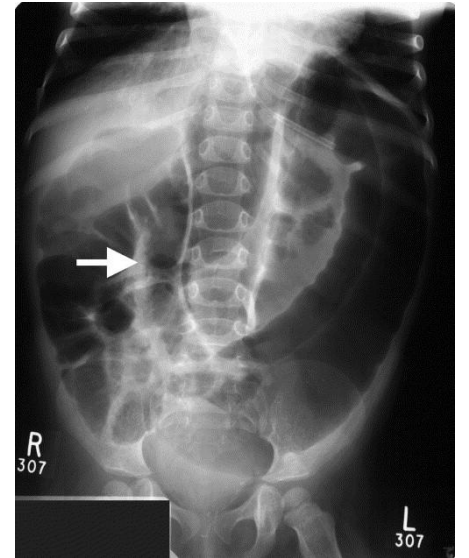
- Clinical suspicion/history
- Contrast enema: contracted rectum
- Rectal (suction or full-thickness) biopsy shows absence of ganglion cells and hypertrophic nerves



Hirschsprung Associated Enterocolitis (HAEC)

- What it is: mild to severe toxicity caused by stool retention
- Can rapidly lead to dehydration, sepsis, cerebral infarcts and death
- Risk factors: Proximal transition zone and Trisomy 21
- Treatment:
 - Rectal IRRIGATIONS, **not** enemas
 - No more than 20/kg retention of saline

https://www.youtube.com/watch?v=Ka_1mKFB6Yk



Hirschsprung Disease in Newborns: Hirschsprung Associated Enterocolitis (HAEC)



HD in Newborns: Surgical management options

Teach family irrigations,
delayed pull-through

- Ideal for rectosigmoid transition zones

Newborn pull-through*

- Ideal for non-toxic, healthy, term infants

Newborn “leveling
colostomy”*

- *** requires frozen section and path expertise**

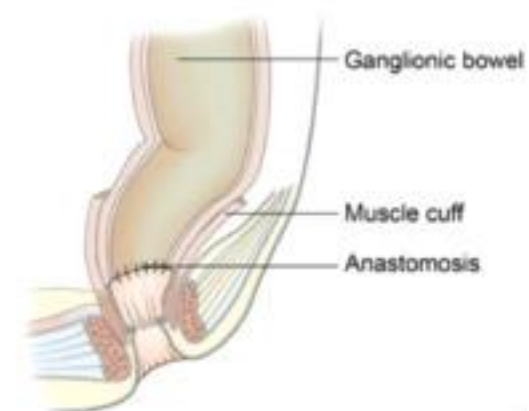
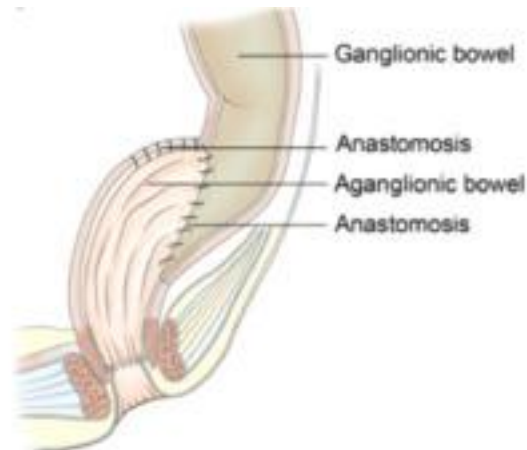
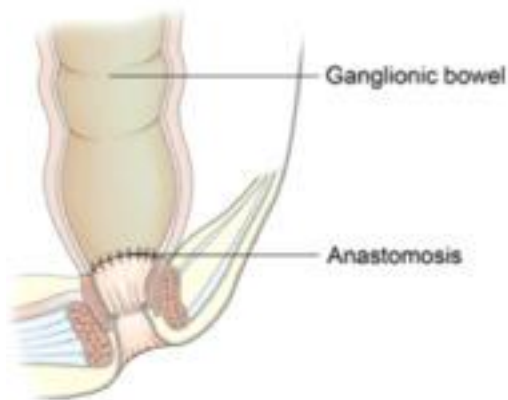
Newborn Bowel Prep

- Mechanical (cleanse) and Antibiotic prep (reduce bacterial load)
- Clear fluids for 24 hours prior to surgery, we may use MiraLAX or oral GoLYTELY drip in some cases
- Day before surgery (oral antibiotics):
 - Neomycin - 15 mg/kg/dose
 - Erythromycin - 10 mg/kg/dose
 - In place of Erythromycin, may substitute Flagyl: 7.5 mg/kg/dose

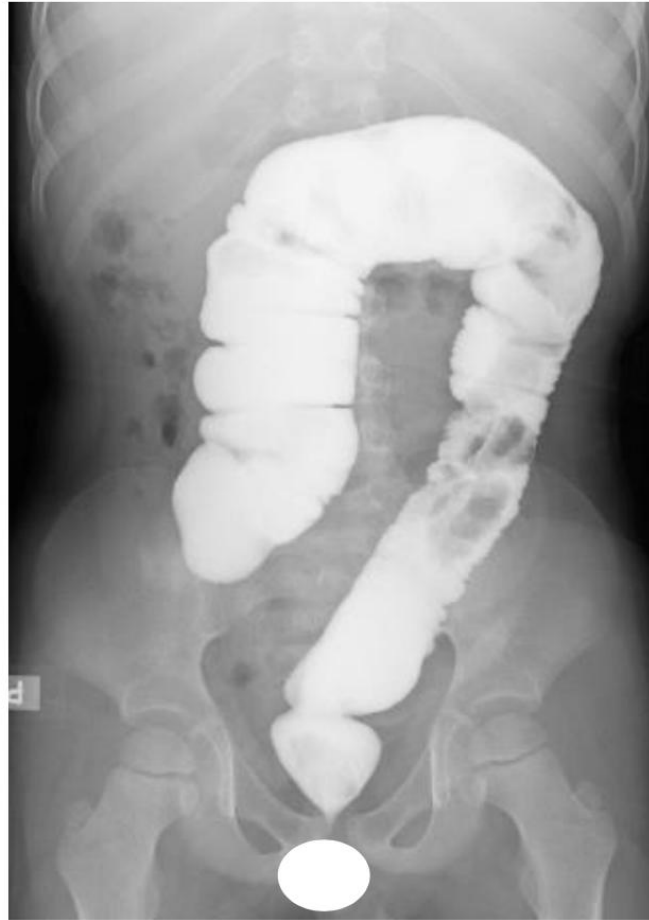Ahmad HA, et al: Decreasing Surgical Site Infections in pediatric stoma closures; J Pediatr Surg, 2020, 55: 90-95

All Pull-throughs are not the same


- Hirschsprung pull through:
 - Swenson: just outside the rectal wall
 - Yancey-Soave: dissect in the rectal wall
 - Duhamel: dissect behind the rectum
 - Georgeson (laparoscopic): like a Swenson in the abdomen and like a Soave through the anus



Any Questions?



Anorectal malformations



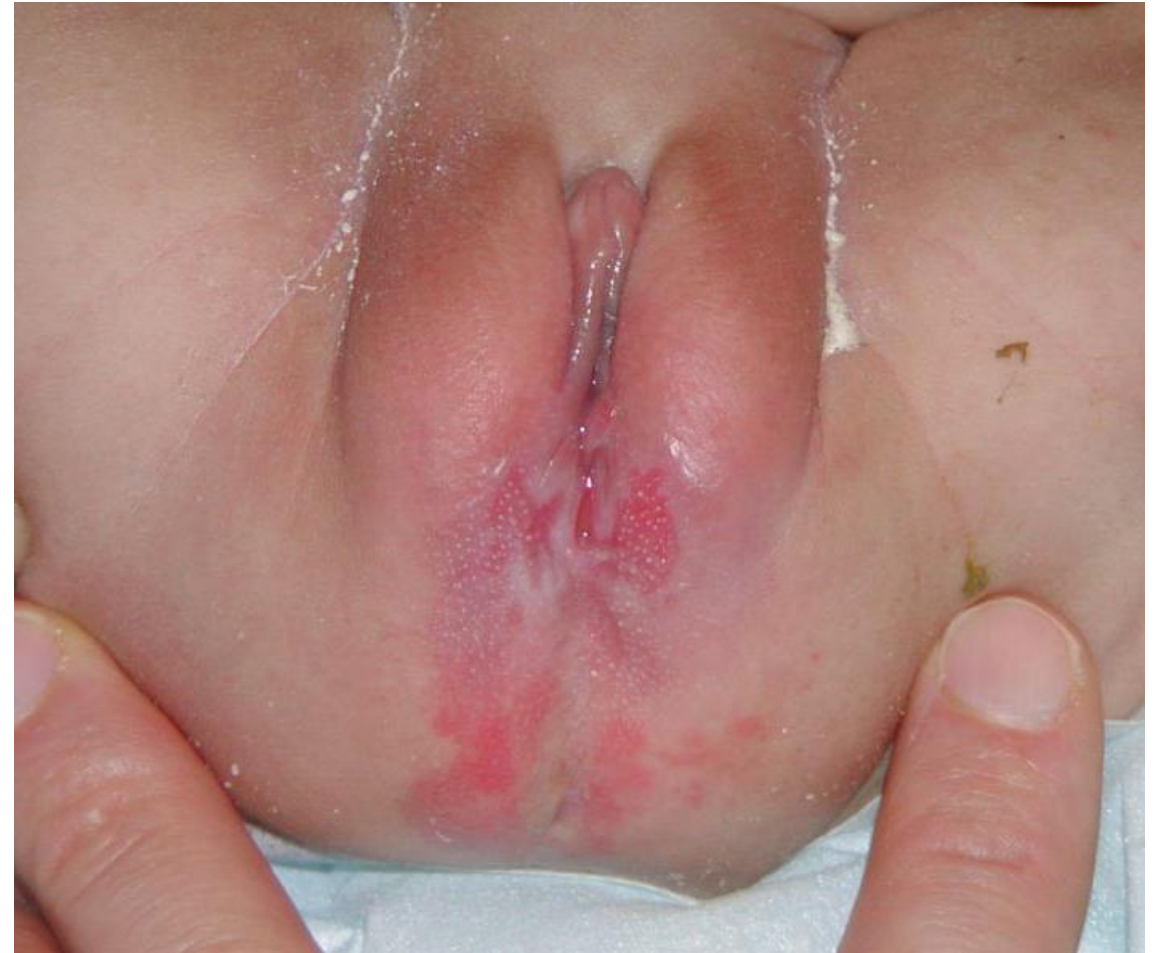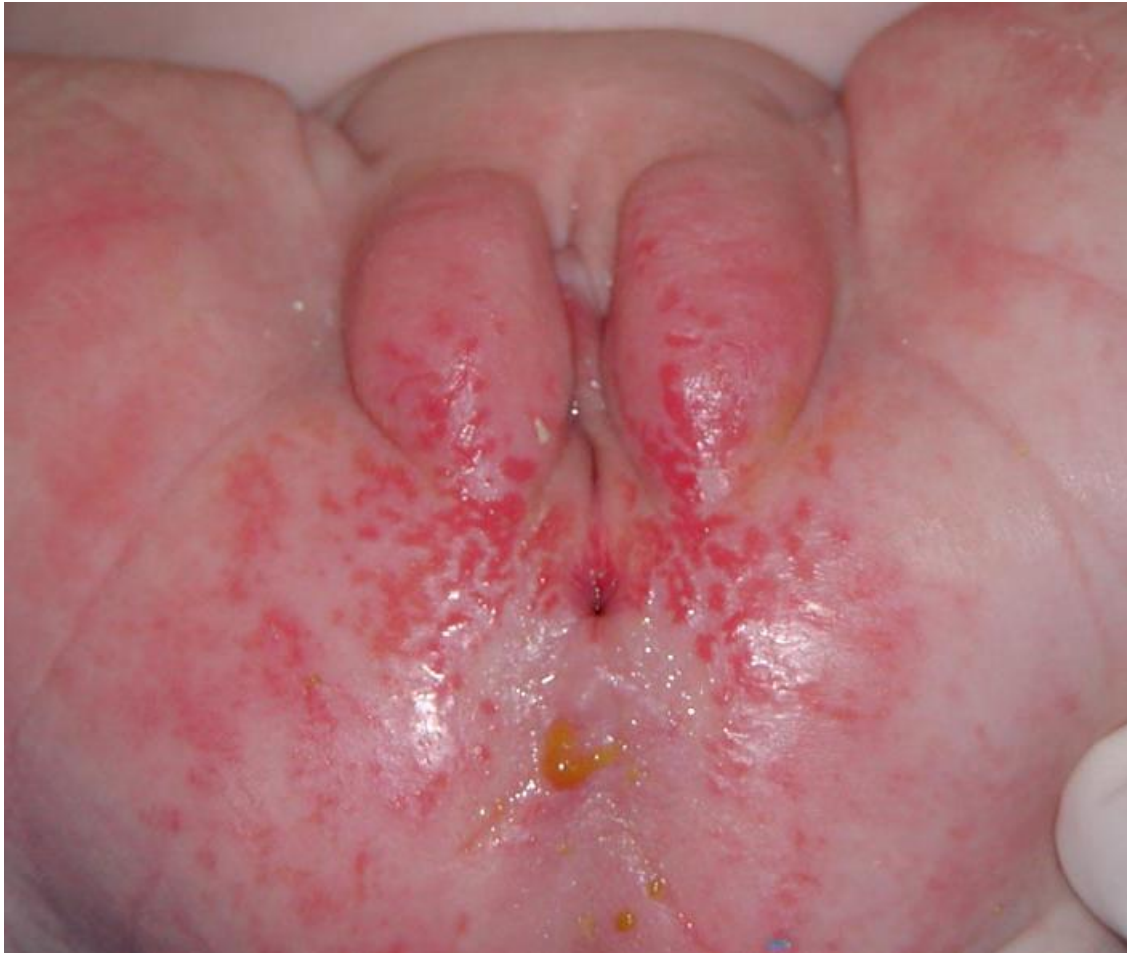Anorectal malformations (ARM)

A wide
spectrum of
abnormalities.

#1 missed lesion
is rectoperineal
fistula in females
and males

Frequently missed anomalies!

Rectoperineal fistula

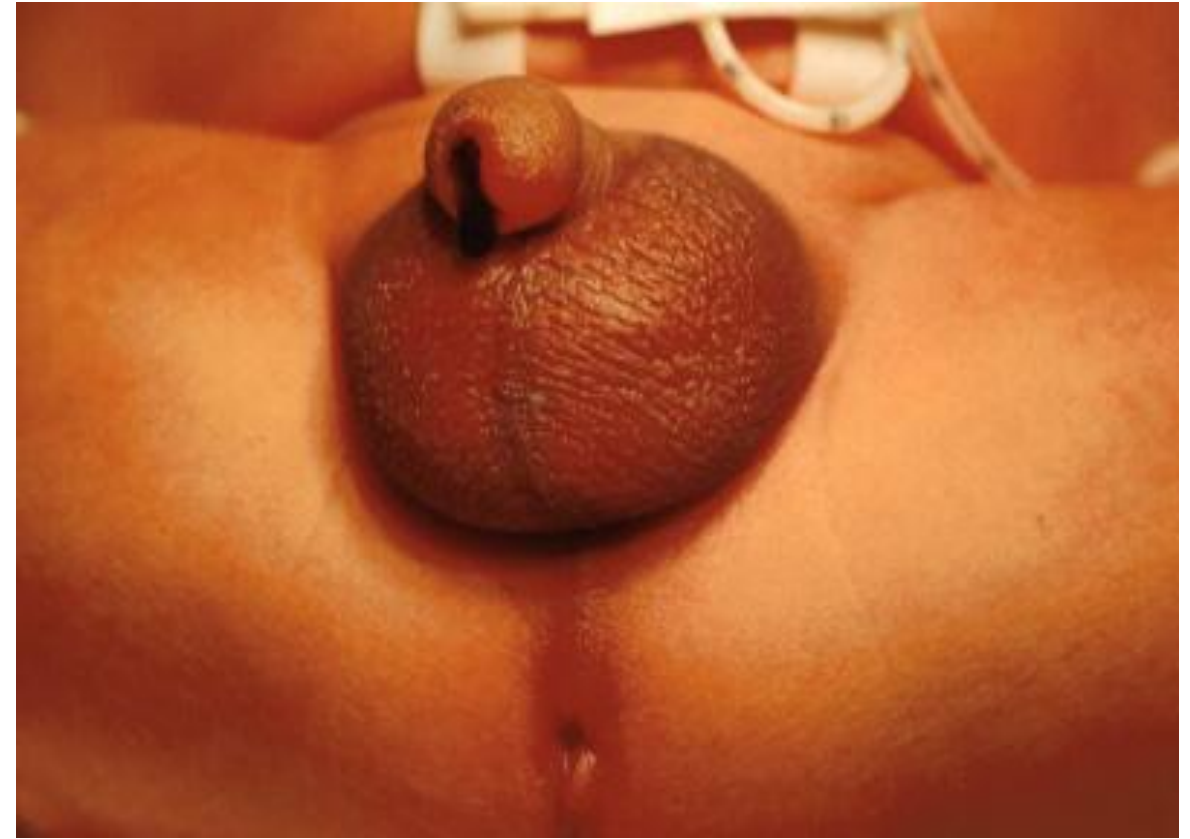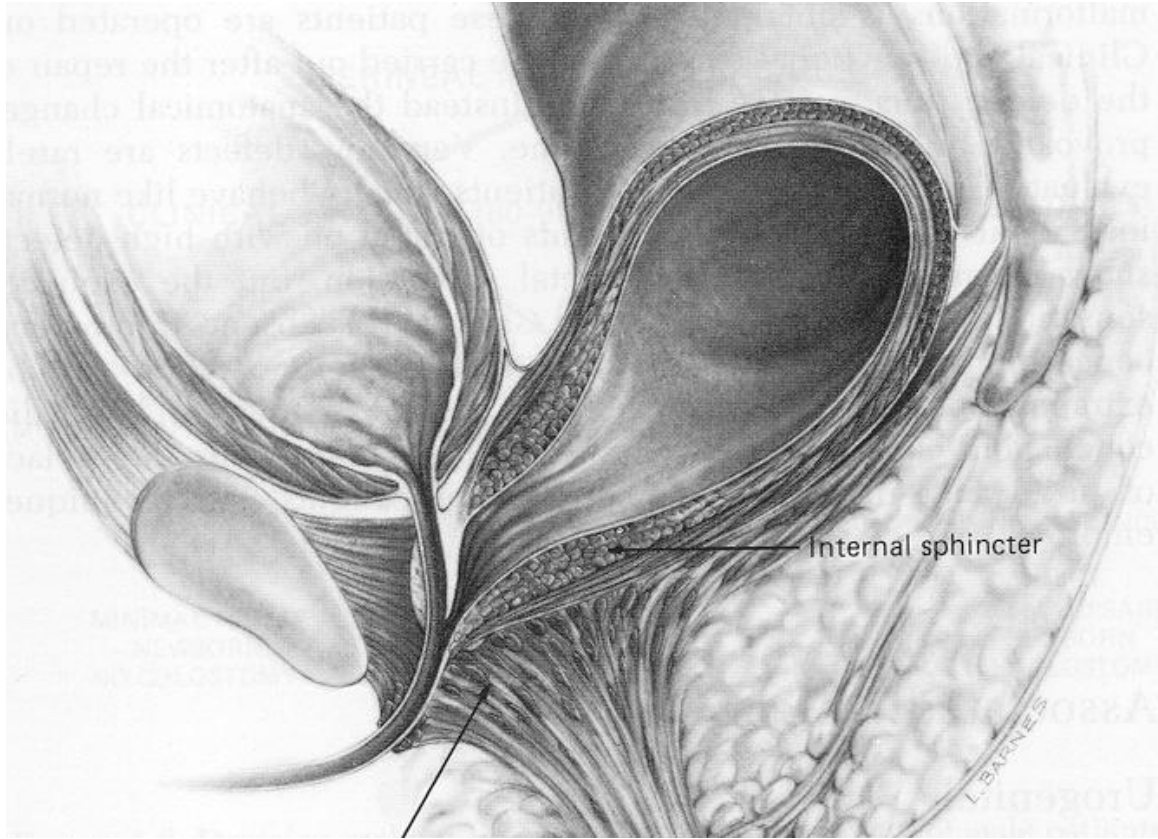


Anorectal malformations

- Most important subtle morbidity is renal insufficiency
- Most important long-term problem is **constipation**

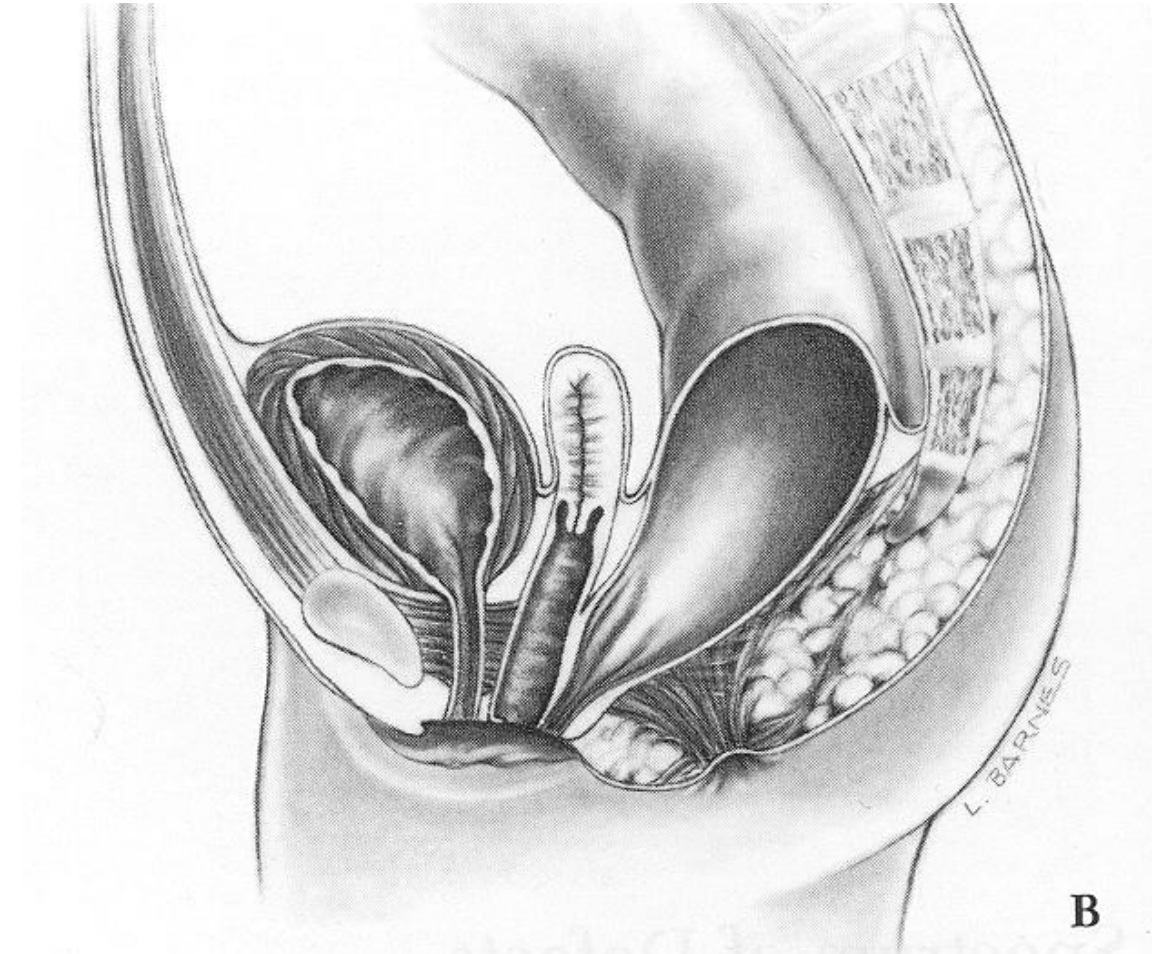
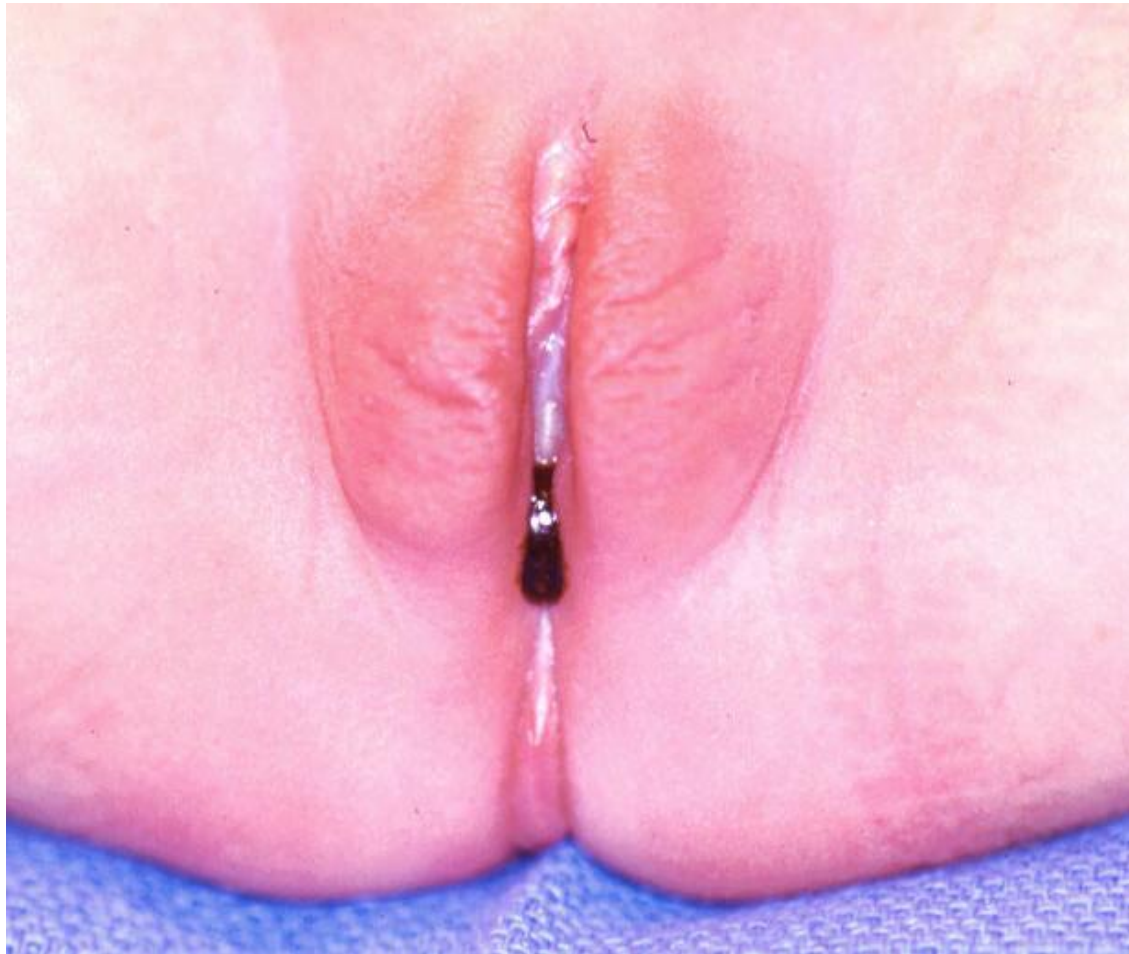Anorectal malformation – Males

MC: Rectoperineal Fistula

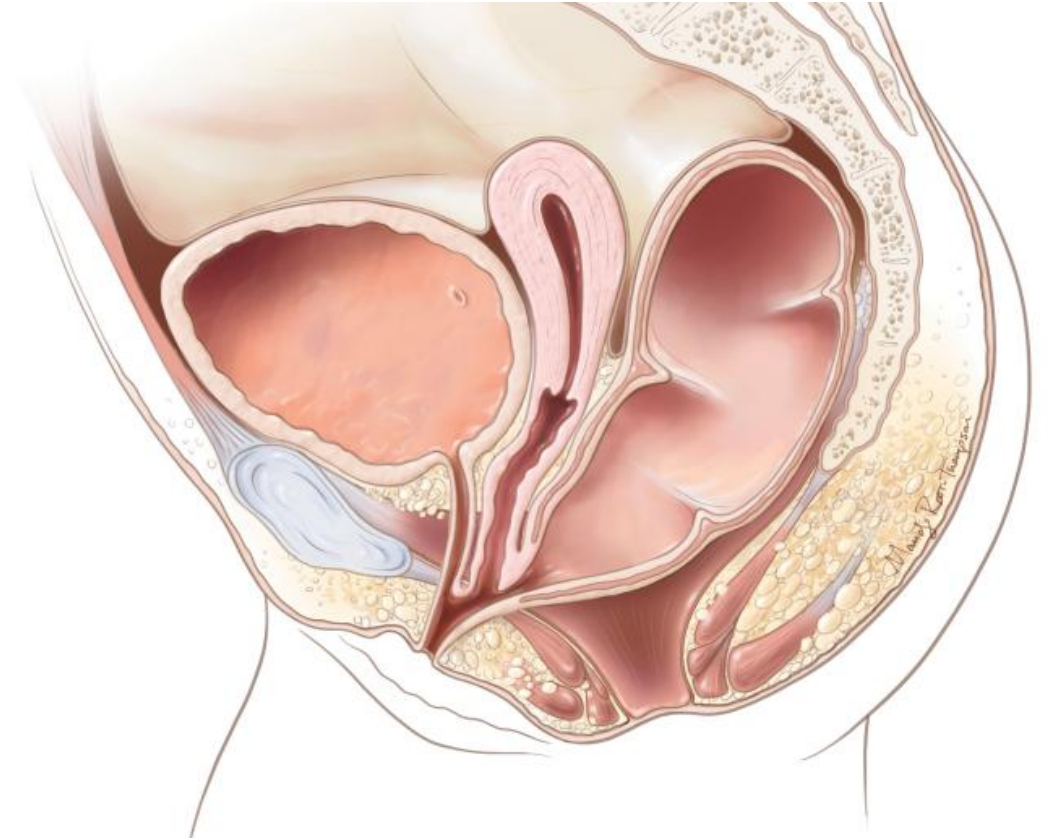
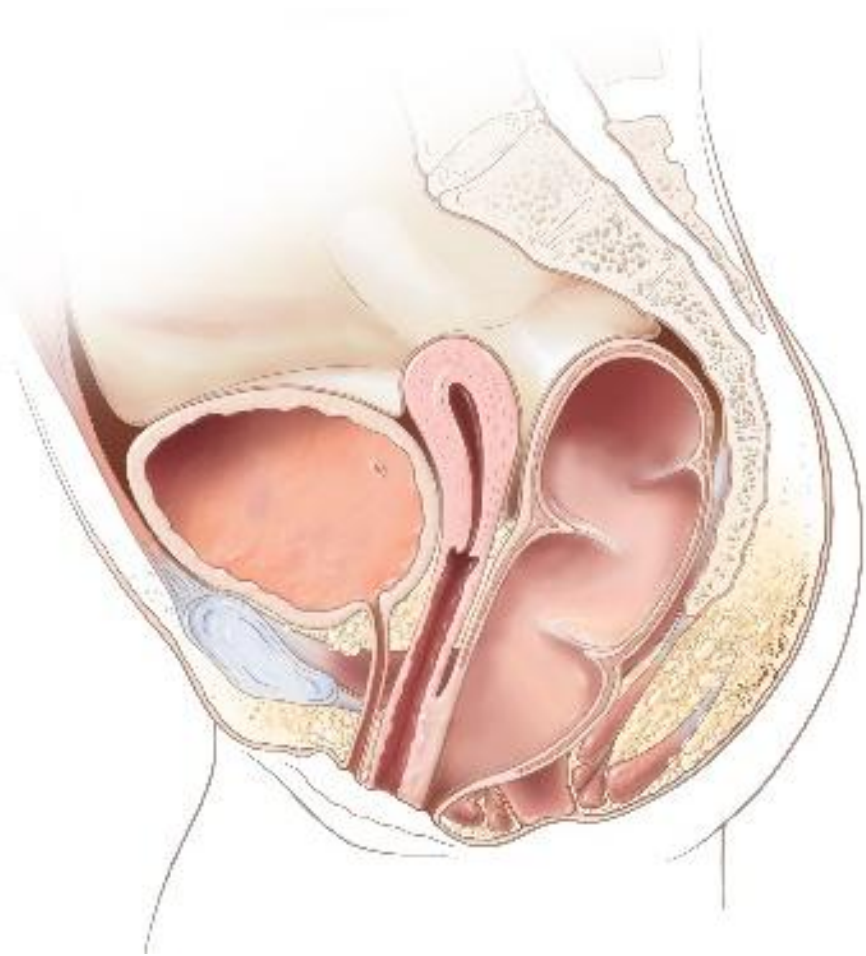


Anorectal malformation – Females

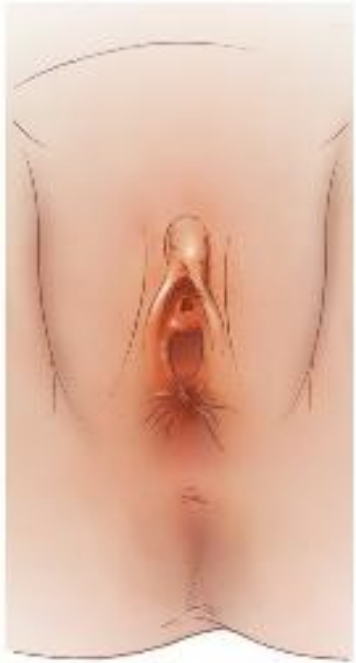MC: Rectovestibular Fistula



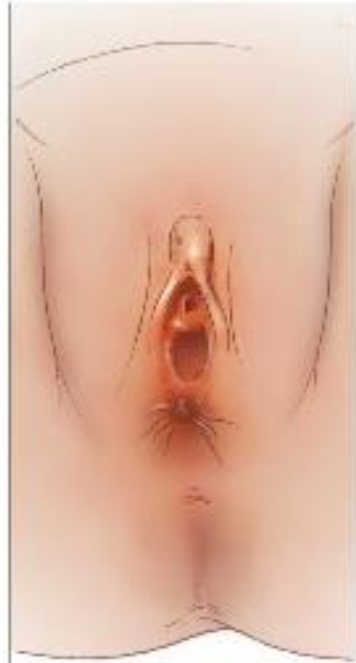Wide spectrum



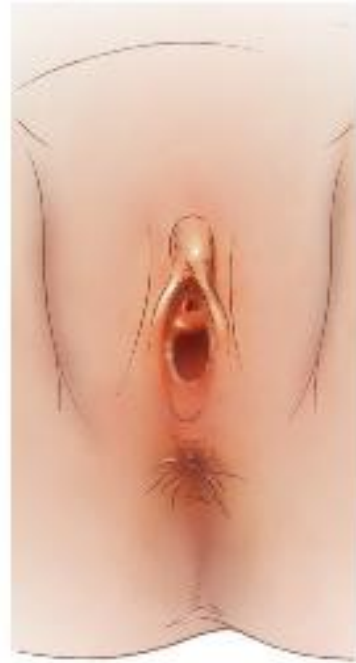Wide spectrum



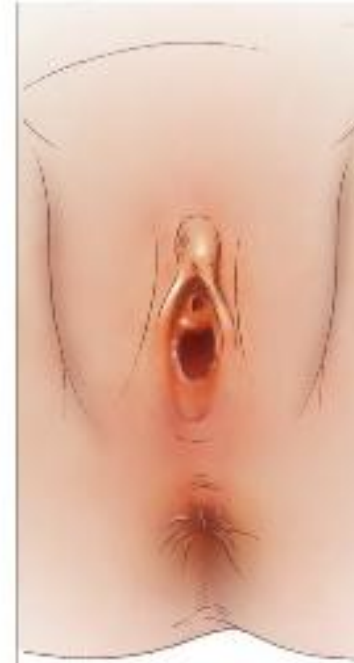
Vestibular



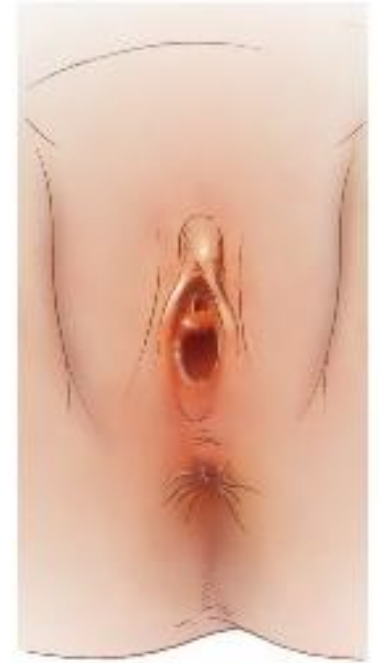Perineal fistula anterior to sphincteric ellipse



Perineal fistula at anteriormost extent of sphincteric ellipse



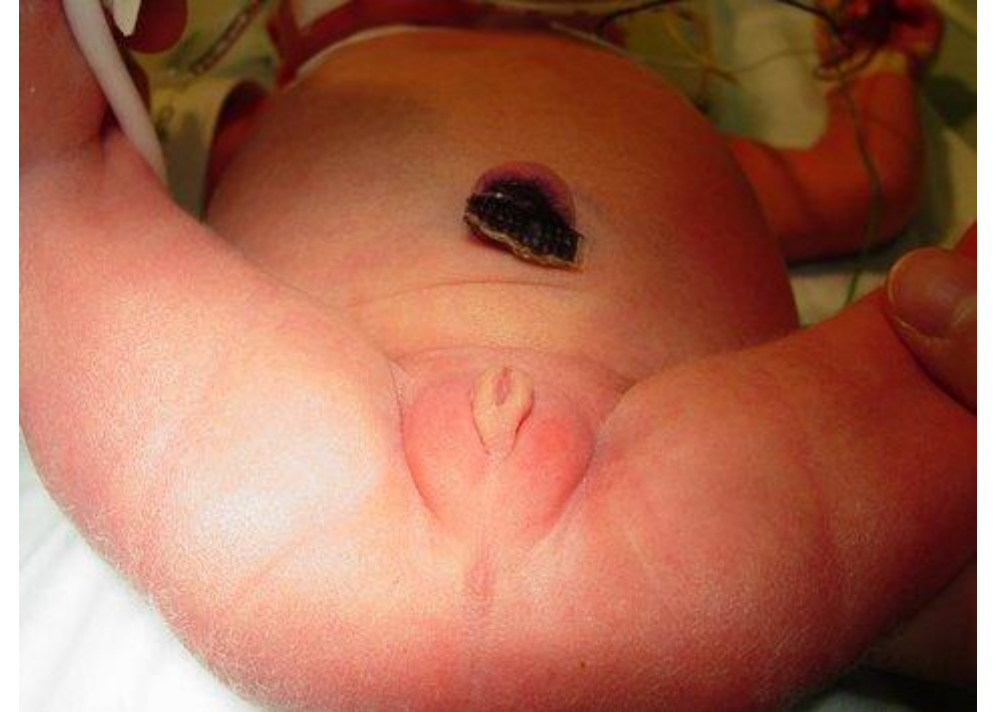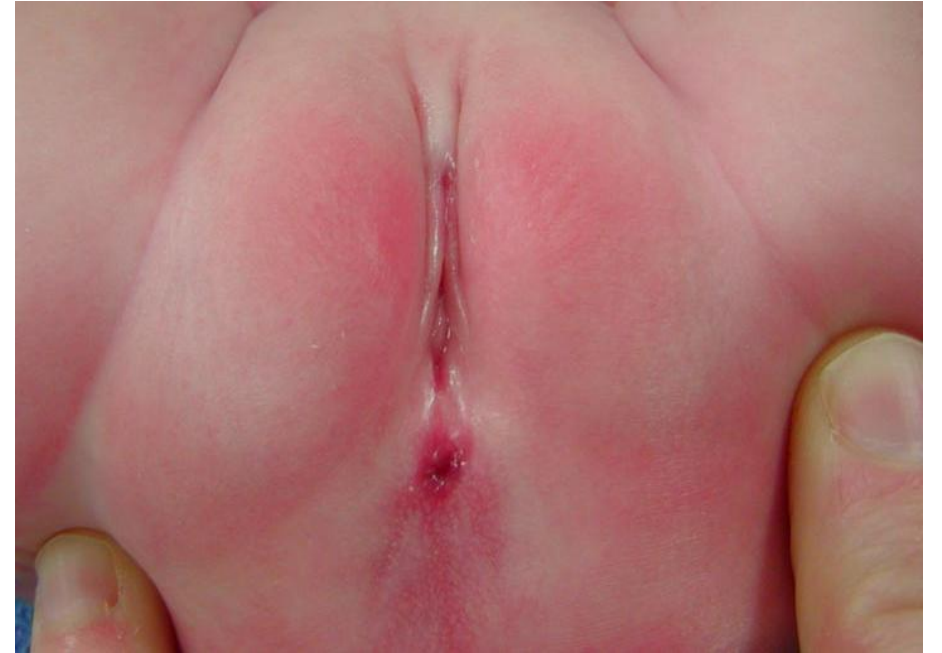Anal stenosis



Normal anus just slightly anteriorly located

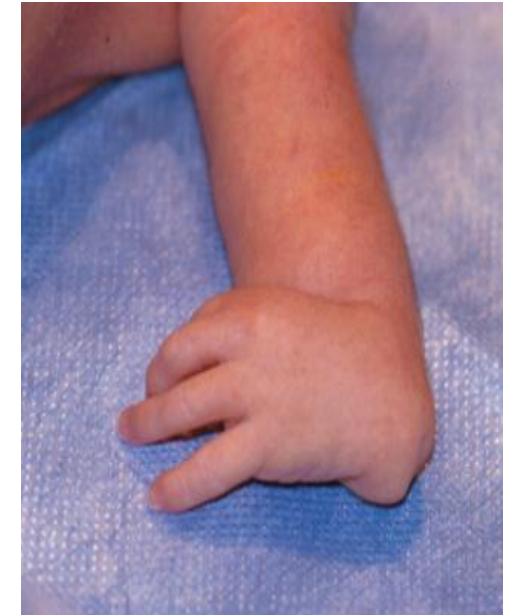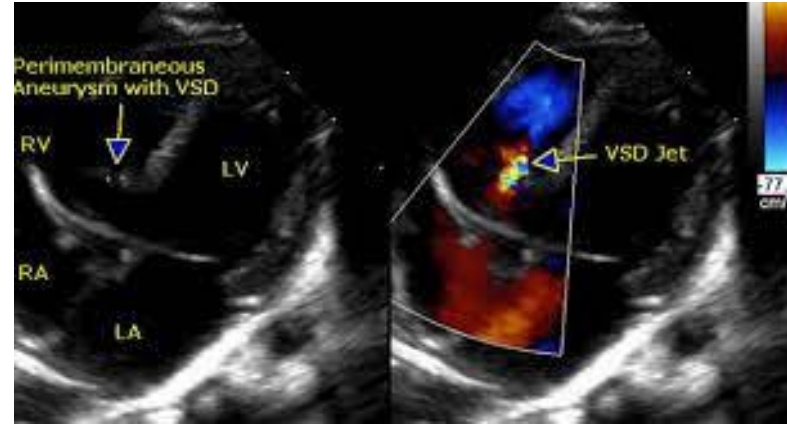
Basic Classification






- Low lesions e.g. rectoperineal, rectovestibular fistula
 - Meconium present soon after birth
 - Relatively straightforward to repair
- High lesions e.g. rectourethral fistula, cloaca
 - Usually no meconium at birth
 - More complex to repair
 - Worse prognosis

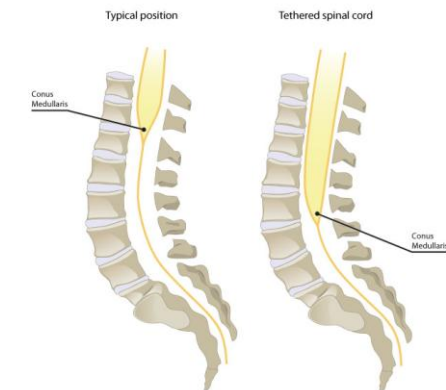
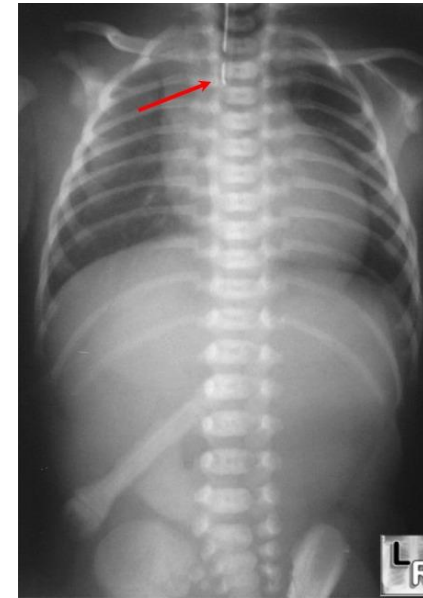

Anorectal malformation: Associated Anomalies

- Vertebral/Spinal
- Anorectal malformation
- Cardiac
- Tracheo
- Esophageal fistula
- Gynecologic
- Renal
- Limb



Radiology	
	Rad-I: Just renal pelvis visible AP: 5-7 mm
	Rad-II: Some calices visible AP: 7-10 mm
	Rad-III: Marked dilation of calices AP > 10 mm
	Rad-IV: Narrowing parenchyme
	Rad-V: Extreme hydronephrosis with only a thin, membrane-like residual parenchymal rim



Imperforate Anus: newborn evaluation

- Vertebral/Spinal
- Anorectal
- Cardiac
- Tracheo
- Esophageal fistula
- Renal
- Limb

Babygram, Spinal US

Careful Inspection

Echo

Pass orogastric tube if suspicious (drooling)

Renal US

Inspection/ ? X rays

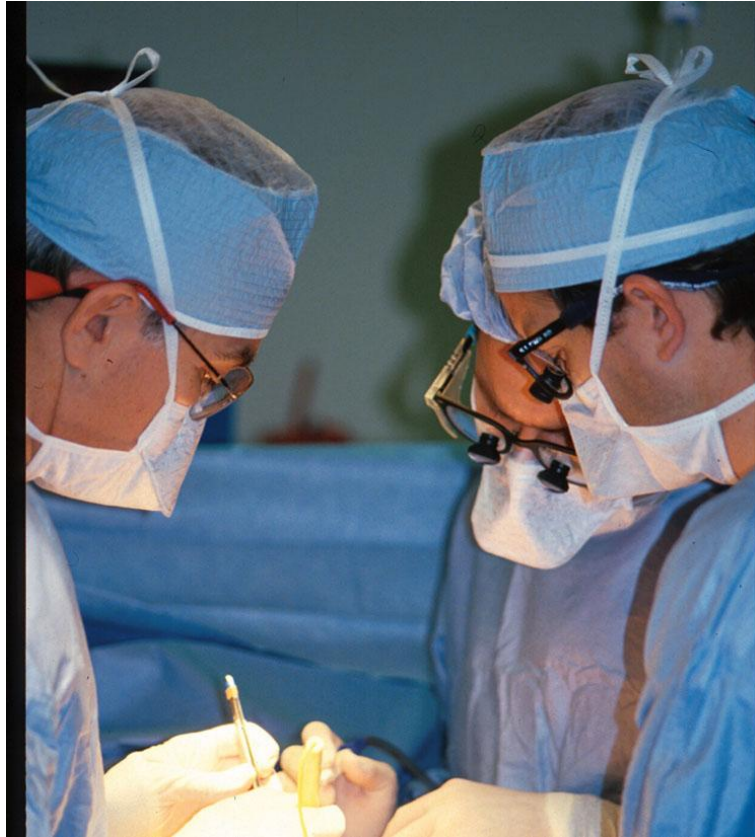
Urinary anomalies in ARM:

- 26% overall incidence
- Incidence increases with more severe anomalies:
 - 52% of males with rectovesical fistula
 - 81% of females with cloacal anomaly
- **SIGNIFICANCE:** more patients will die from renal failure than will die from fecal incontinence

ARM: Basic Steps in Surgical Treatment

- +/- Colostomy Formation
- Anal Reconstruction
 - Open (PSARP) or
 - laparoscopic repair
- +/- Postoperative Anal Dilatation
- +/- Colostomy Closure

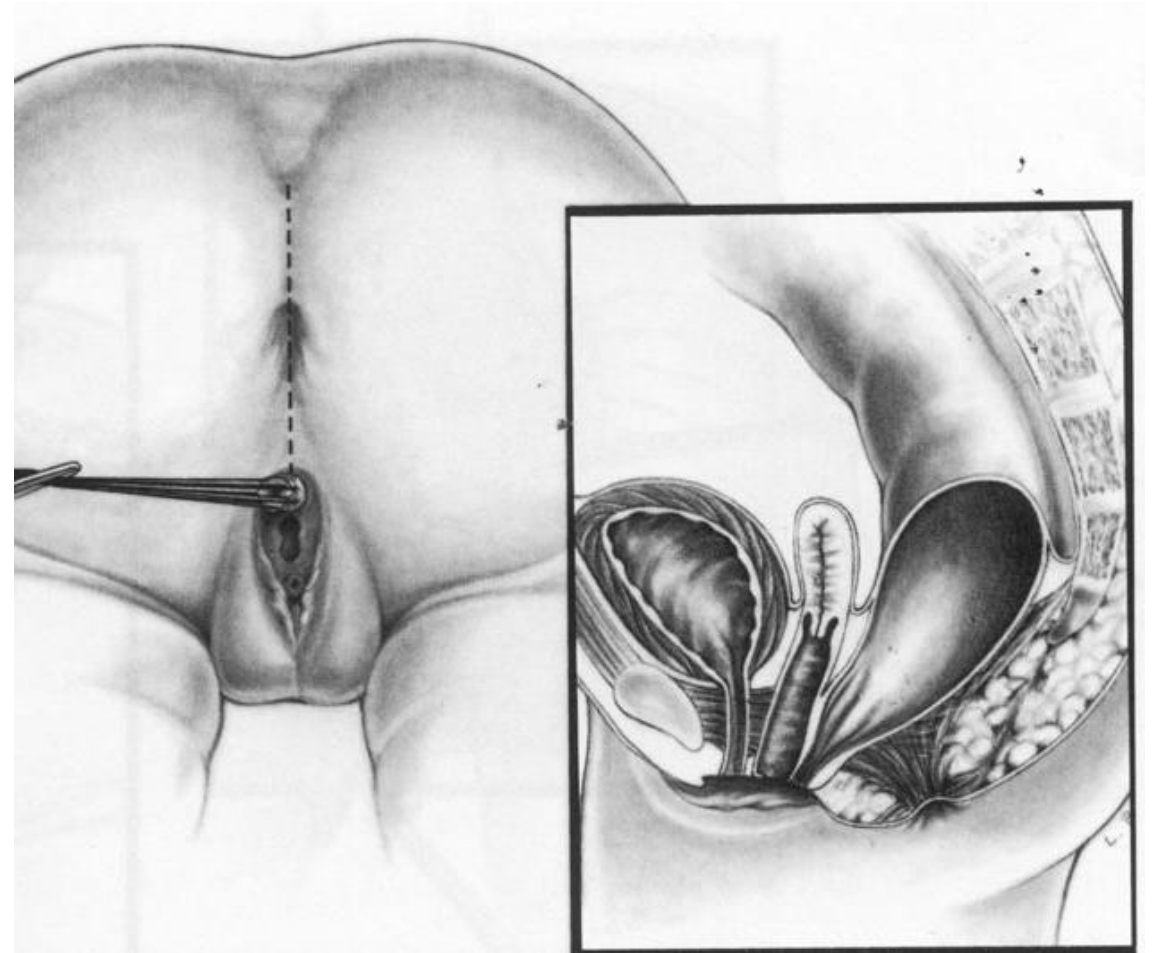
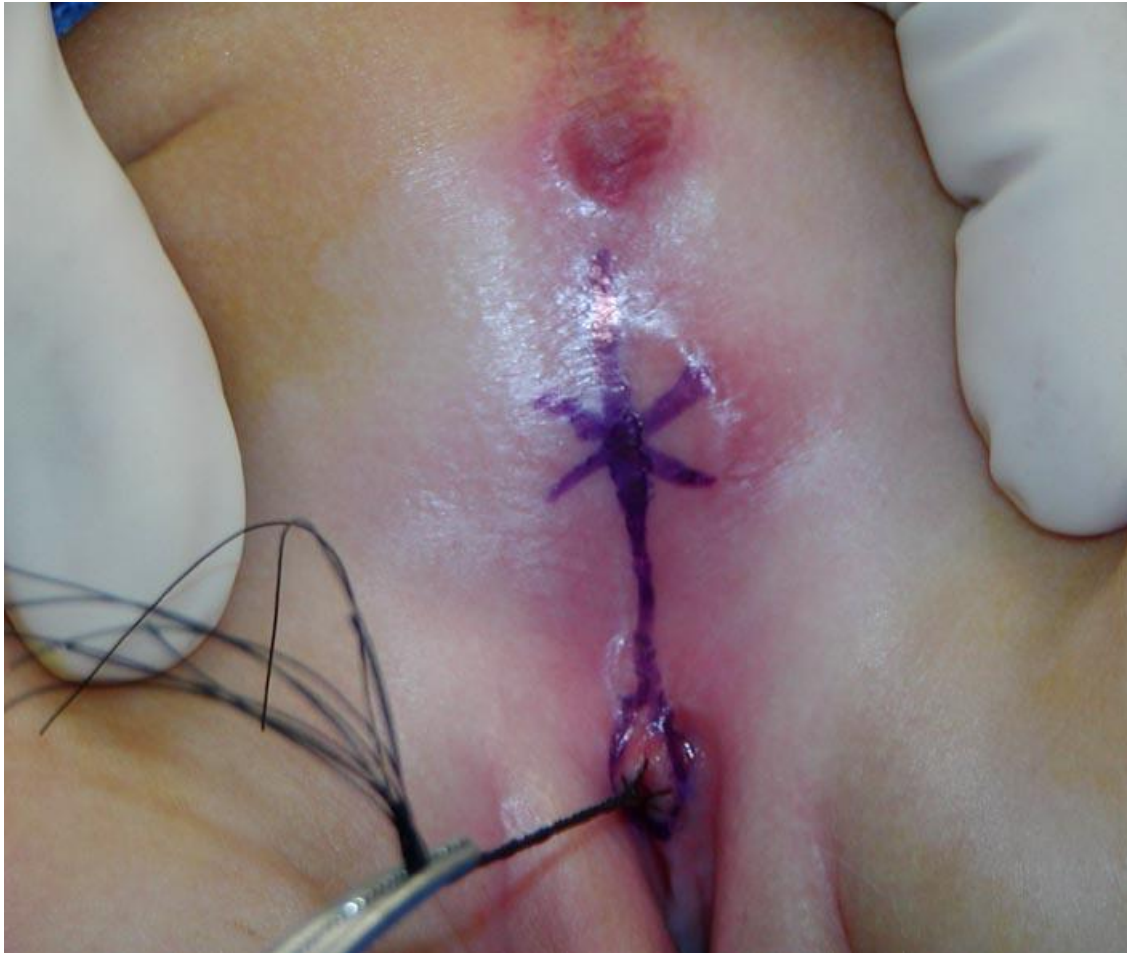Posterior Sagittal Anorectoplasty “PSARP”



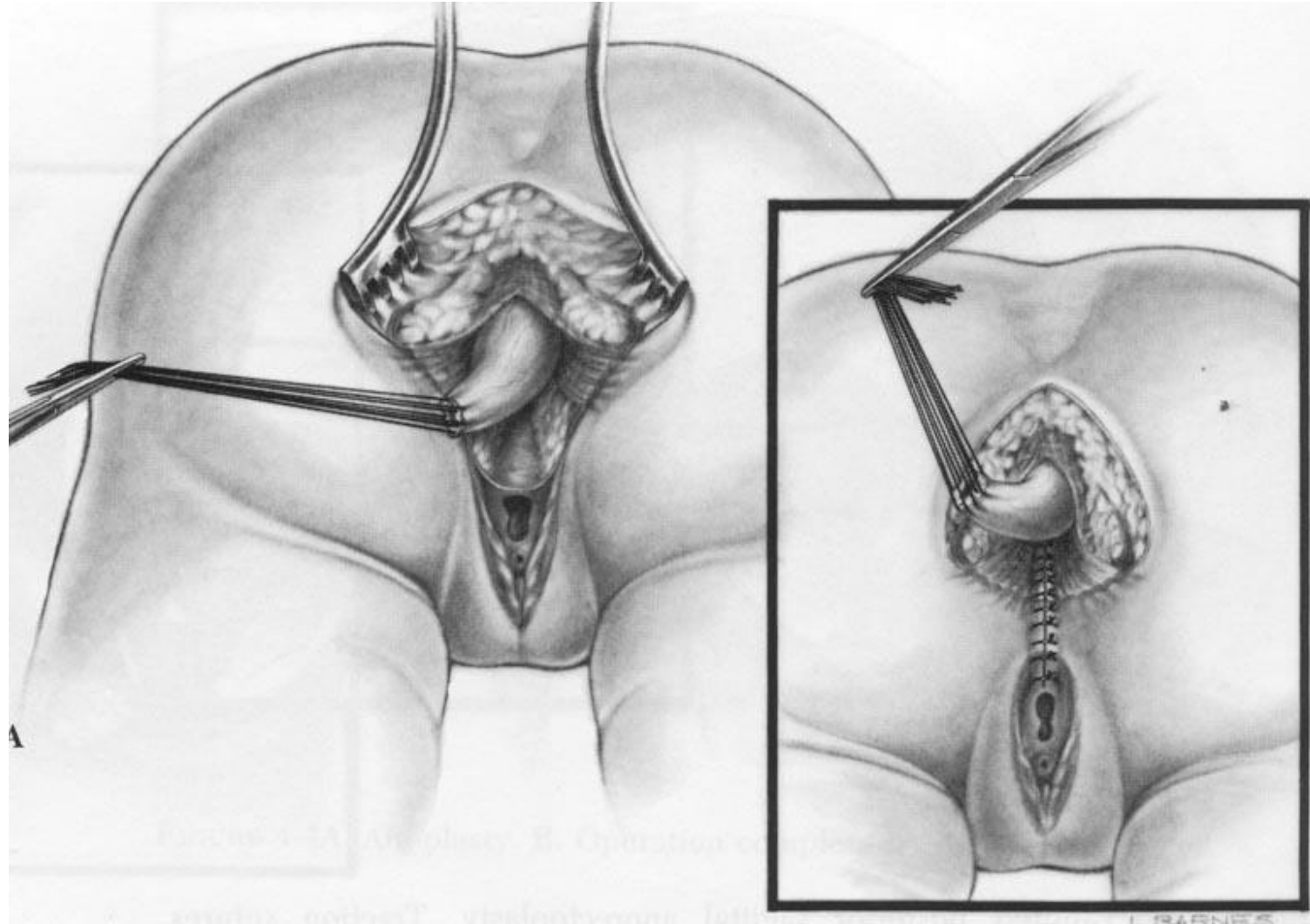
- Original description: 1982 deVries, Pena
- Posterior midline incision
- Sphincter anatomy “directly visualized”

[Experts in Surgery | CCPR Surgical treatment of recto-vestibular fistula - \(No Audio\)](#)

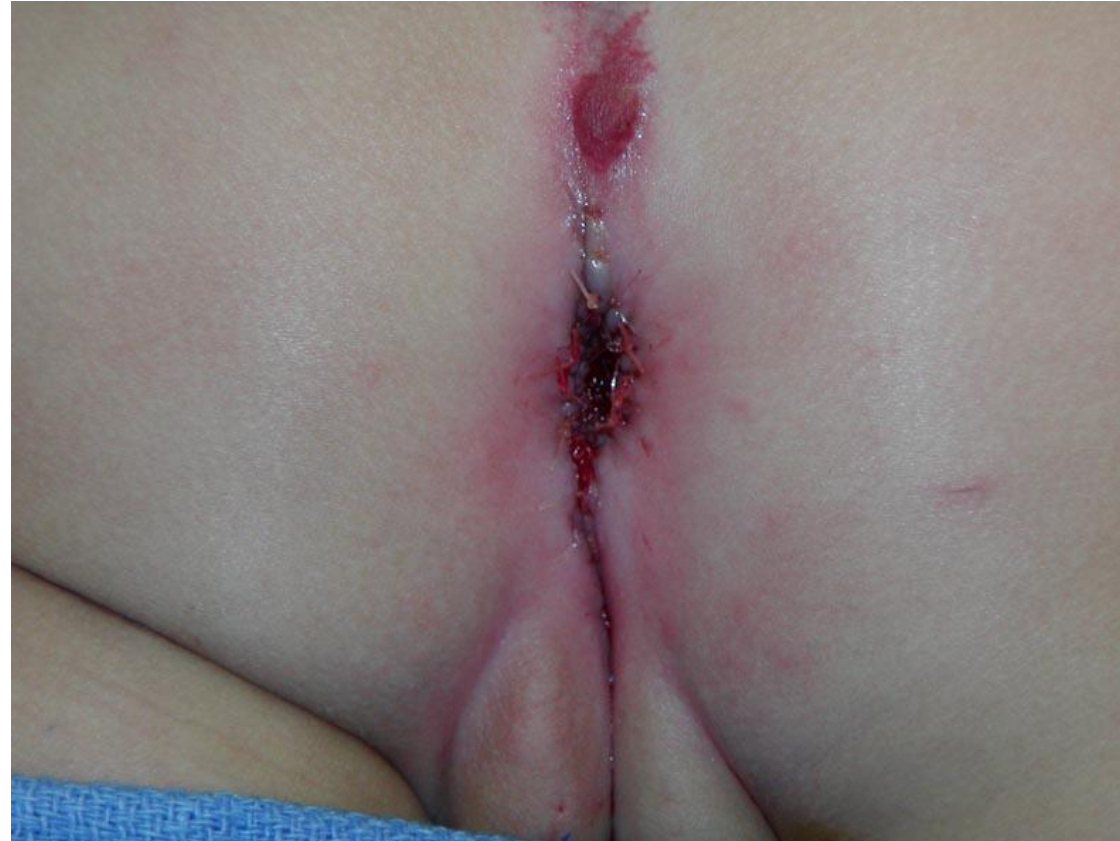Female with rectovestibular fistula



Female with rectovestibular fistula

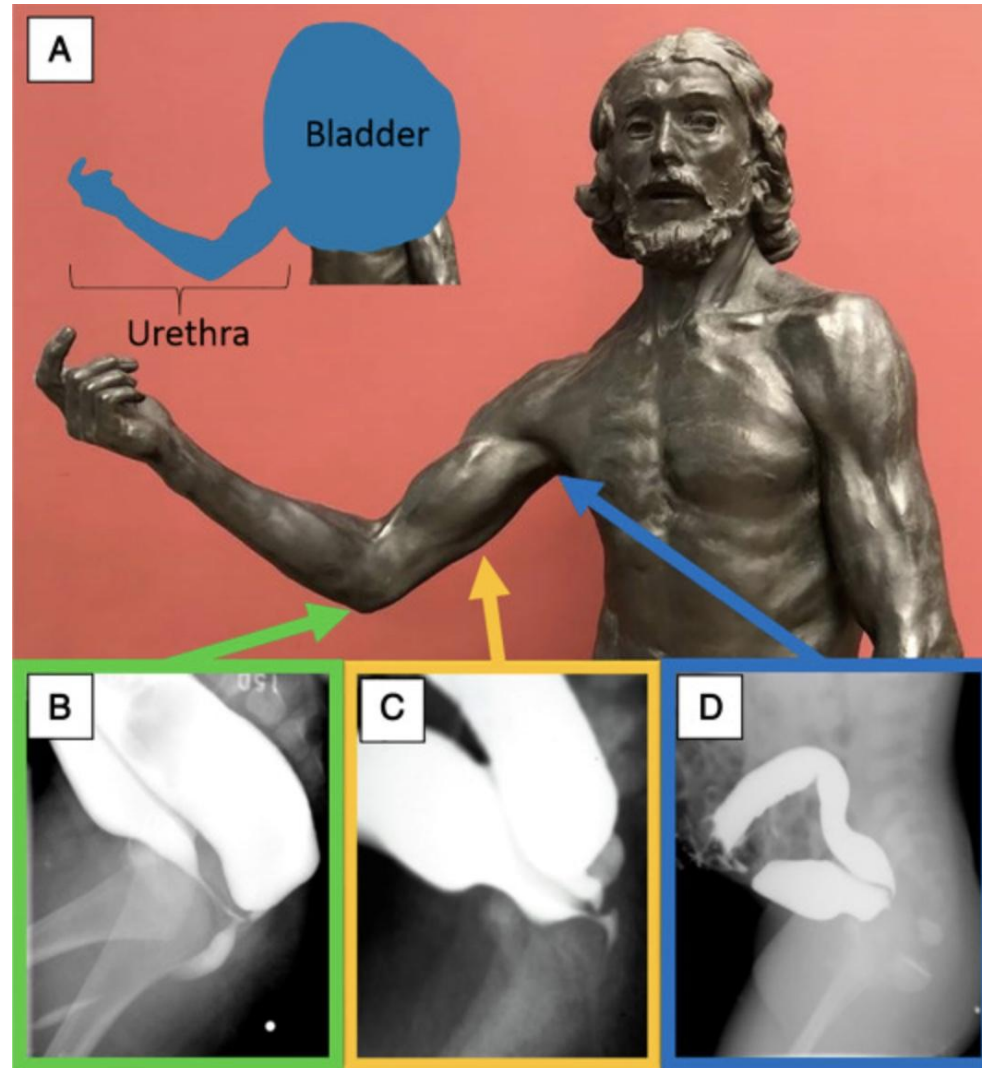


Female with rectovestibular fistula

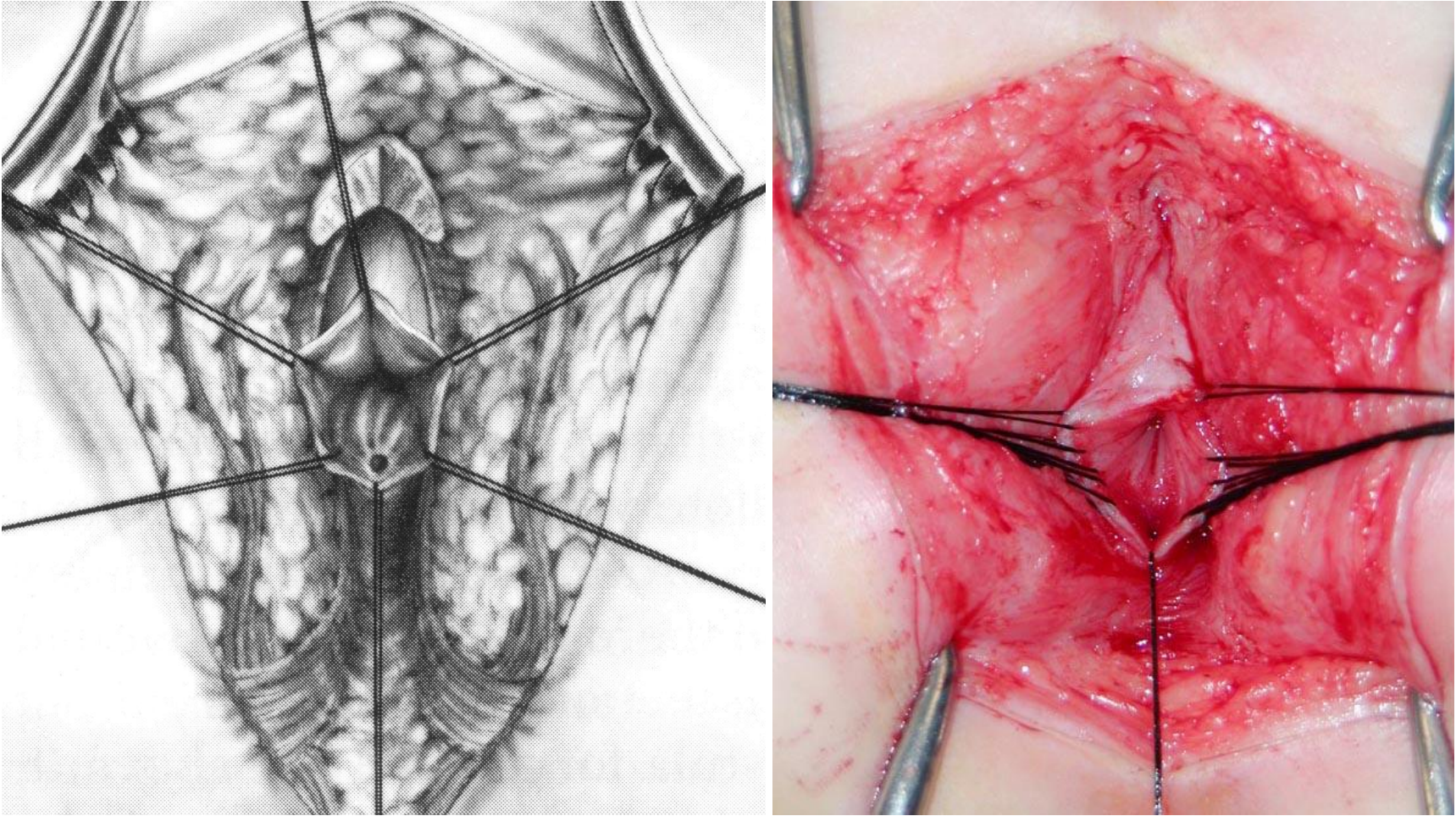


ARM: Males Preoperative dye study is critical

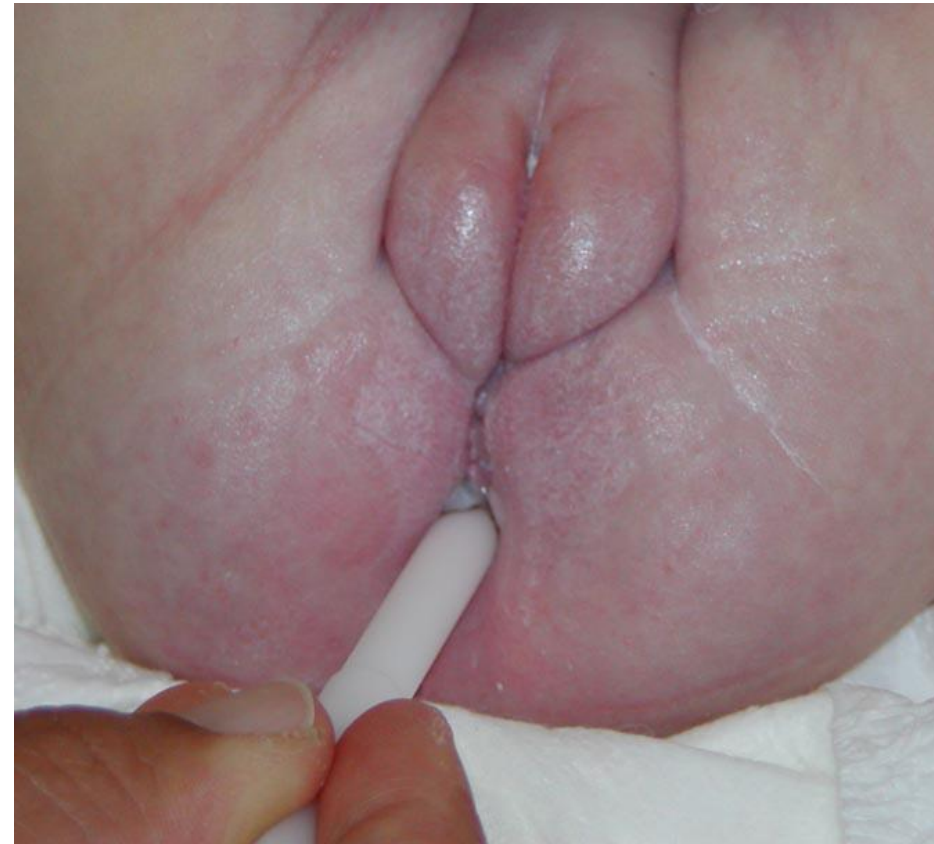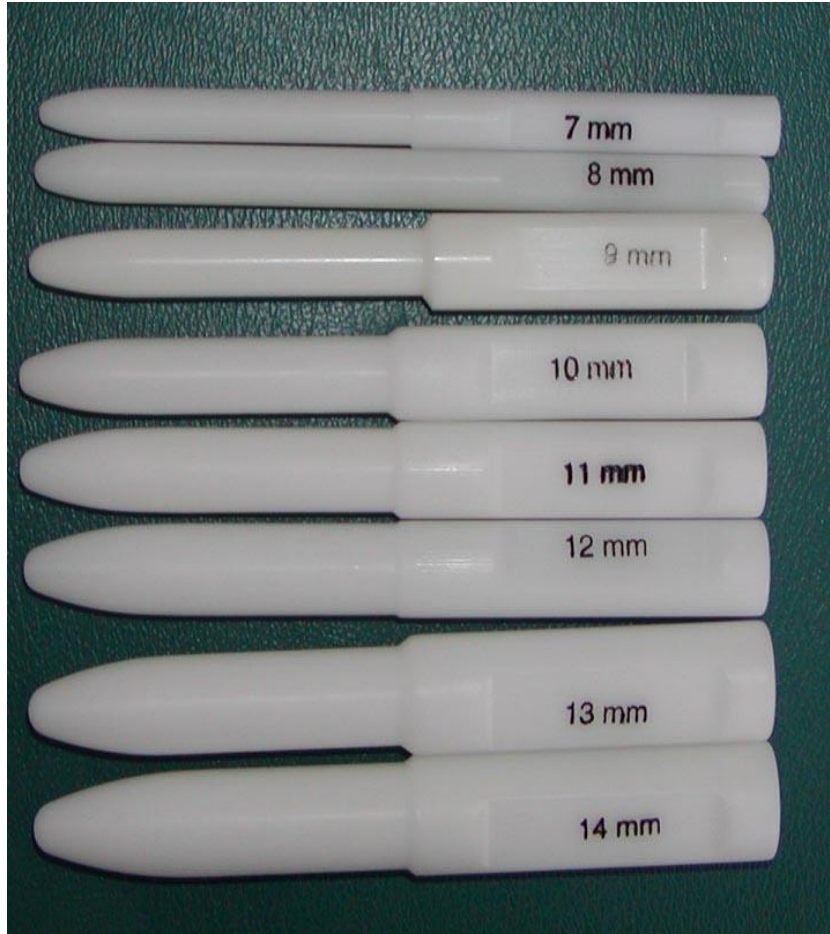
One of the main reasons for mucus fistula



Male with rectourethral fistula



Postop Anal Dilatations



A New Way of Thinking & Emotional Safety

Learning to insert a dilator can feel very scary and stressful for both parents and children.

The Risk of Trauma: Recent studies have shown that the traditional, rigid dilation routine can sometimes cause significant emotional distress, leading to Post-Traumatic Stress Disorder (PTSD) in both children and parents. The fear of pain and the daily struggle can create long-term anxiety around bathrooms and medical care.

New research: Because of these concerns, brand-new studies are showing that not dilating at all may have equally good results for many children. In some cases, the body heals with a wide enough opening on its own, and avoiding forced stretching leads to better emotional outcomes and less pain.

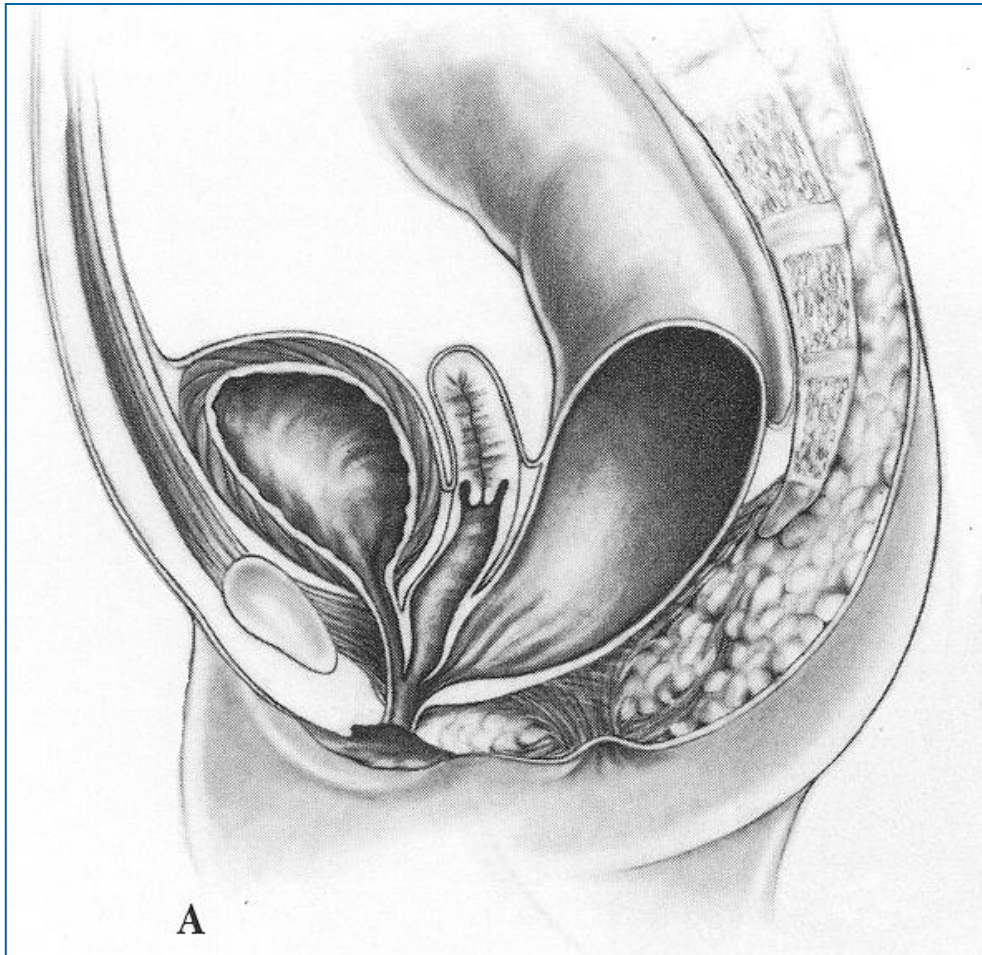
Post Surgical Management

Perianal Rashes

- *Chemical Irritation*
 - Use barrier protectants, cortisone (e.g. Calmoseptine, A&D, Ilex, Criticaid)
- *Fungal Infection*
 - Satellite lesions, especially in folds
 - Clotrimazole, mycostatin creams
 - Apply under barrier protectants



Long Term: Fecal Continence



Intact anal sphincter complex

Normal Spine

Type of malformation

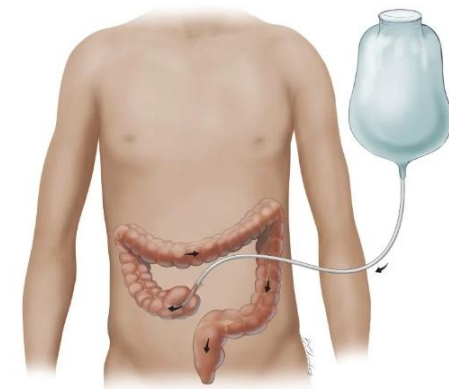
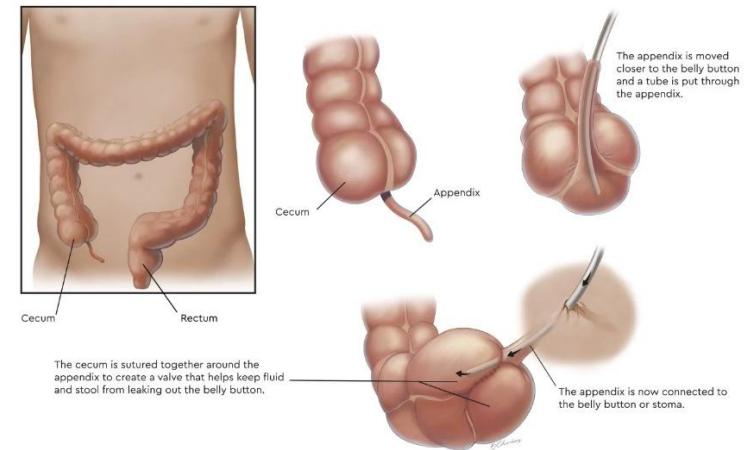
Control improves over years, 20-40% still need bowel management

Long-term issues

- Constipation
- Fecal Incontinence

Bowel Management Strategies

- Avoid impaction: laxatives (Senna), Metamucil
- Avoid stool softeners (MiraLAX)
- Control rectal emptying
 - Timed defecation
 - Suppositories and enemas
- Surgery
 - No “artificial sphincter” available
 - Antegrade enema conduits possible
- Pelvic floor physical therapy



PCPLC



Parent's Support Group

Pull-Thru Network



Conclusions

- Patients with Hirschsprung Disease are usually continent but can get septic with enterocolitis, which can be fatal
- Anorectal Malformations (ARM) comprise a wide range of anomalies and defects
- ARM patients will rarely get seriously ill, but will struggle with fecal incontinence and long-term renal issues

Bibliography

- Stevenson RE, Hunter AG. Considering the Embryopathogenesis of VACTERL Association. *Mol Syndromol*. 2013 Feb;4(1-2):7-15. doi: 10.1159/000346192. PMID: 23653571; PMCID: PMC3638783.
- Wood RJ, et al. One-year impact of a bowel management program in treating fecal incontinence in patients with anorectal malformations. 2021 Apr;56 (1689-1693. Doi <https://doi.org/10.1016/j.jpedsurg.2021.04.029>
- Frykman PK, Short SS. Hirschsprung-associated enterocolitis: prevention and therapy. *Semin Pediatr Surg*. 2012 Nov;21(4):328-35. doi: 10.1053/j.sempedsurg.2012.07.007. PMID: 22985838; PMCID: PMC3462485.
- Warne SA, Wilcox DT, Ledermann SE, Ransley PG. Renal outcome in patients with cloaca. *J Urol*. 2002 Jun;167(6):2548-51; discussion 2551. PMID: 11992086.
- Halleran DR, Ahmad H, Bates DG, Vilanova-Sanchez A, Wood RJ, Levitt MA. A call to ARMs: Accurate identification of the anatomy of the rectourethral fistula in anorectal malformations. *J Pediatr Surg*. 2019 Aug;54(8):1708-1710. doi: 10.1016/j.jpedsurg.2019.04.010. Epub 2019 Apr 26. PMID: 31076157.
- Bischoff A, Levitt MA, Peña A. Laparoscopy and its use in the repair of anorectal malformations. *J Pediatr Surg*. 2011 Aug;46(8):1609-17. doi: 10.1016/j.jpedsurg.2011.03.068. PMID: 21843731.
- De Vos C, Arnold M, Sidler D, Moore SW. A comparison of laparoscopic-assisted (LAARP) and posterior sagittal (PSARP) anorectoplasty in the outcome of intermediate and high anorectal malformations. *S Afr J Surg*. 2011 Mar 14;49(1):39-43. PMID: 21933483.
- Kessmann J. Hirschsprung's disease: diagnosis and management. *Am Fam Physician*. 2006 Oct 15;74(8):1319-22. PMID: 17087425.
- Worman S, Ganiats TG. Hirschsprung's disease: a cause of chronic constipation in children. *Am Fam Physician*. 1995 Feb 1;51(2):487-94. PMID: 7840044.
- Gosain A, Frykman PK, Cowles RA, Horton J, Levitt M, Rothstein DH, Langer JC, Goldstein AM; American Pediatric Surgical Association Hirschsprung Disease Interest Group. Guidelines for the diagnosis and management of Hirschsprung-associated enterocolitis. *Pediatr Surg Int*. 2017 May;33(5):517-521. doi: 10.1007/s00383-017-4065-8. Epub 2017 Feb 2. PMID: 28154902; PMCID: PMC5395325.
- Soh HJ, Nataraja RM, Pacilli M. Prevention and management of recurrent postoperative Hirschsprung's disease obstructive symptoms and enterocolitis: Systematic review and meta-analysis. *J Pediatr Surg*. 2018 Dec;53(12):2423-2429. doi: 10.1016/j.jpedsurg.2018.08.024. Epub 2018 Se
- Rentea RM, Noel-MacDonnell JR, Bucher BT, Dorman MR, Lautz TB, Pruitt LCC, Oyetunji TA. Impact of Botulinum Toxin on Hirschsprung-Associated Enterocolitis After Primary Pull-Through. *J Surg Res*. 2021 May;261:95-104. doi: 10.1016/j.jss.2020.12.018. Epub 2021 Jan 7. PMID: 33422904.p 4. PMID: 30236605.

LONG LIVE CHILDHOOD

Contact: Name / hahmad@choc.org

