



CHOC Children's Hospital
Best Evidence and Recommendations

**Peripherally Inserted Central Venous Catheter (PICC) Optimal Tip
Placement & Maintenance**

Pernilla Fridolfsson BSN, RNC-NIC, VA-BC
pfridolfsson@choc.org

PICO: In neonatal and pediatric patients requiring a PICC line, does a catheter tip positioned in the distal superior vena cava cause less complication than other non-central tip locations?

P (Population/problem): Neonatal and pediatric patients requiring a PICC line

I (Intervention/issue): Catheter tip location in the distal superior vena cava - lower ½ to 1/3 of SVC

C (Comparison): Other non-central tip locations

O (Outcome): Minimize complications

Background:

Pediatric and neonatal patients are at high risk for developing complications associated with central line access. In particular, children with congenital and acquired heart disease are at risk, due to limited access sites and complex venous anatomy, as well as the inherent risks of repeated invasive procedures and exposure to sedation (King, Da Cruz, & Kaufman, 2010). Smaller vessel diameters resulting in decreased blood flow, causing turbulence and prolonged intimal contact of infusates and catheter tip. This increases the risk of endothelial injury, thrombophlebitis, thrombosis, and potential infection.

A non-centrally placed catheter exacerbates complications and may cause chronic mechanical and/or chemical irritation. Malpositioned catheters are associated with increased morbidity and mortality, and cost of care (Colacchio et al., 2012; Racadio et al., 2001)

The purpose of this project was to develop a standardized approach to ensuring optimal tip placement defining a target tip placement zone for upper and lower limb placements in order to:

- Increase practice consistency among all practitioners
- Utilize current evidence-based research
- Prevent/minimize complications
- Decrease additional procedures and interventions
- Decrease patient morbidity
- Promote safe care
- Increase patient satisfaction
- Decrease health care costs

Additionally, best practices for radiographic imaging and post insertion follow-up x-rays were identified for the neonatal and the pediatric populations. Nuances specific to cardiac patients were also addressed.

Search Strategies and Databases Reviewed:

- Databases searched for this review included Pub Med, CINAHL, Ovid, Cochrane Review, with over 100 articles reviewed ranging from 2000-2016. Eleven articles were selected as the key



documents to model the evidence based practice change. In addition, evidence-based practice recommendations from multiple professional organizations (i.e. FDA, INS, NANN, AVA & NAVAN) and policies from Cincinnati Children's Hospital were reviewed.

Synthesis of the Evidence:

Extensive literature review on best tip placement of a PICC line resulting in the least amount of complications in neonates and children including cardiac patients was narrowed down to 12 articles, ranging from 2000-2016 (most articles from 2008-2016).

- Based on current practice guidelines and evidence-based research, centrally placed catheter tips are associated with fewer complications than non-centrally placed catheter tips.
- Complication rates nearly double in non-central placed lines.
- Central catheter tip placement locations include the SVC, cavo-atrial junction & IVC.
- Non-central catheter tip placement locations are the Subclavian vein, Axillary vein & Brachiocephalic vein.
- FDA, INS, NANN, AVA & NAVAN recommend the lower 1/2-1/3 of SVC as the optimal tip location.
- The most reliable radiographic landmark to define the upper and lower boundaries of the SVC is the "Right Tracheobronchial Angle". The distance from carina to the cavo-atrial junction is 2.0 vertebral body units \pm 0.4
- Catheter tip migration occurs at a higher percentage within the first 24 hours post insertion, requiring x-ray verification to avoid complications.
- A common theme among all articles reviewed was patient and family education regarding home pain control. Throat pain is greatest the first few days following surgery, and may last up to 2 weeks; pain is also worse in the morning.

Practice Recommendations:

- The optimal upper limb catheter tip location is the distal superior vena cava (SVC)- lower $\frac{1}{2}$ to $\frac{1}{3}$ of SVC (Baskin et al., 2008; Doellman et al., 2015; Infusion Nurses Society, 2011; Mason Wyckoff & Sharp, 2015; United States Food & Drug Administration, 1989).
- The most reliable radiographic landmark to define the upper and lower boundaries of the SVC is the "Right Tracheobronchial Angle" (Baskin et al., 2008; Connolly et al., 2000; Hostetter et al., 2010; Vesely, 2003).
- Distance from carina to the cavo-atrial junction is 2.0 vertebral body units \pm 0.4 (Baskin et al., 2008).
- CHOC Children's should use 1.5 (not to exceed 1.7) vertebral units as the target zone to guarantee tip placement outside the right atrium. Target triangle: Carina – 1.5 vertebral units – right main bronchus (see upper limb figure).
- The optimal lower limb catheter tip location is in the high IVC between T9 - T11 (see lower limb figure) (Mason Wyckoff & Sharp, 2015; Racadio et al., 2001).
- When placing a PICC line in the left lower leg and there is a slight zigzag appearance of the catheter and/or a radiographic inguinal curl occurs, consider obtaining a cross-table, lateral film to exclude paraspinal misplacement (Chedid et al., 2005).



- A chest X ray to determine appropriate tip placement should be performed:
 - Directly after insertion.
 - Repeat X ray is required if ≥ 1 cm adjustments in the neonatal and the pediatric population.
 - Post PICC insertion follow-up X ray within 12-24 hours of insertion to be done next morning (0600-0800) (Gupta et al., 2016; Mason Wyckoff & Sharp, 2015).
 - Every 2 weeks to assess for migration.
 - When an x-ray is obtained for any purpose where PICC tip may be visualized, the radiographic analysis should always include a description of tip location.
 - For upper extremity PICC placement: Ensure patient is supine, both arms are adducted, and head midline.
 - For lower extremity PICC placement: Ensure patient is supine, legs are in neutral adducted position (slightly bent).

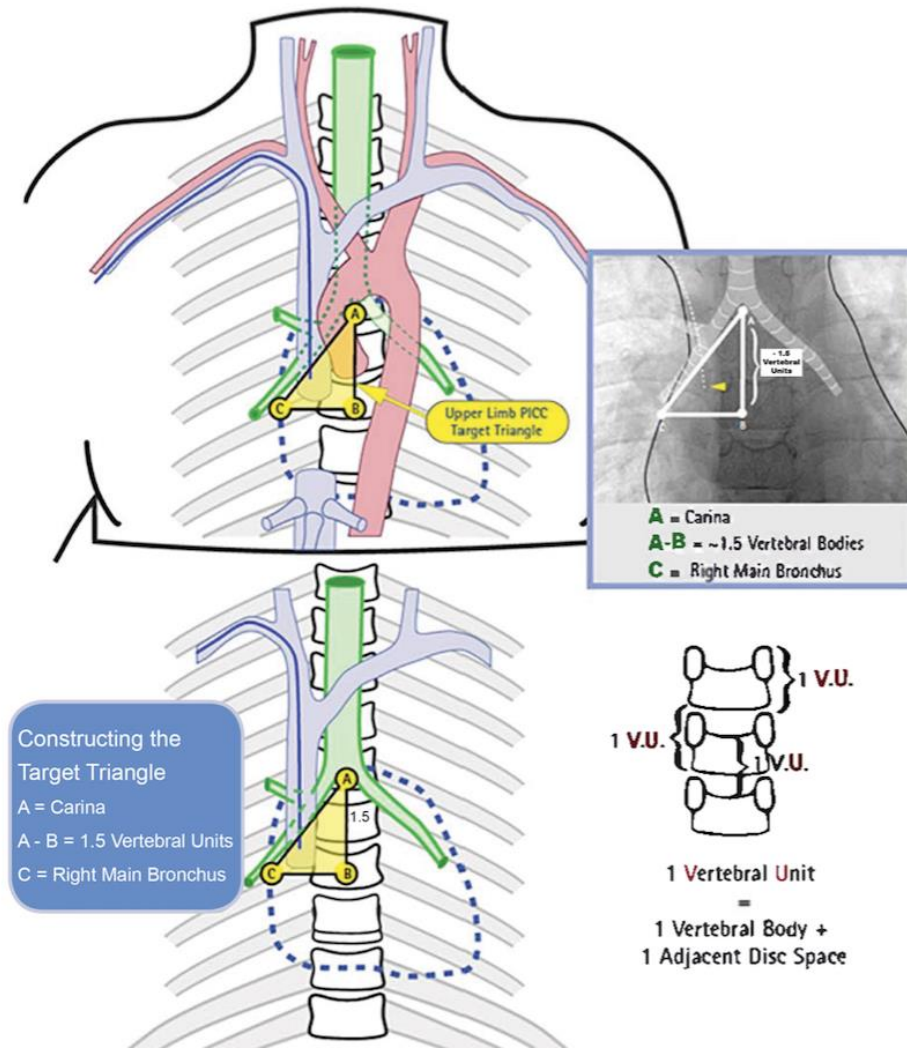
- For the patients with the following single ventricle physiology:
 - Atrial atresia
 - Mitral atresia
 - Pulmonary atresia
 - Tricuspid atresia
 - Unbalanced AV canal
 - Hypoplastic left heart syndrome
 - Cardiac heterotaxy defects
 - Use the smallest catheter to complete the therapeutic goal (generally 3Fr PICC line is used to obtain laboratory samples and give blood products).
 - Place PICC line in lower extremities, preferably left leg. Right leg is used for heart catheterization.
 - If there are issues or questions consult with cardiothoracic surgeon.

- Exclusion Criteria: Exceptions to non-central PICC tip placement would include the rare circumstance when central PICC placement is not possible (i.e. patients with single ventricle physiology when the left lower extremity is not accessible or patients with limited vascular access as determined by the provider).

- Discuss all non-central/malpositioned PICC tips with the attending physician.



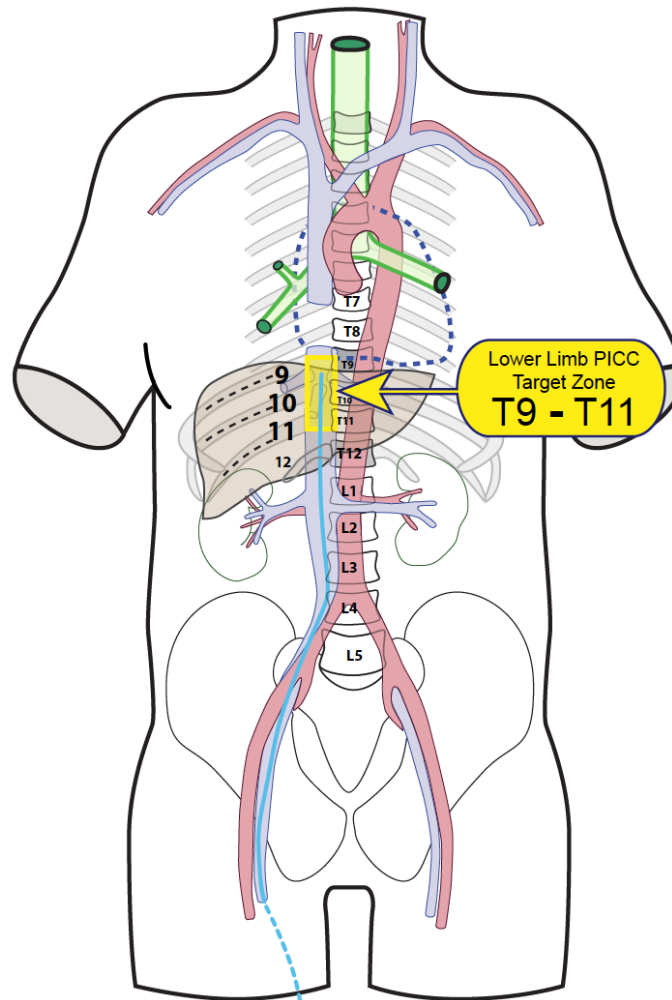
Upper Limb PICC Target Zone:
CHOC Children's Hospital's target zone is 1.5 vertebral units not to exceed 1.7.



(Figure modified from Cincinnati Children's Hospital, 2012)



Lower Limb PICC Tip Target Zone:
CHOC Children's Hospital's target zone is T9-T11.



(Cincinnati Children's Hospital, 2012)

Acknowledgments:

- The Evidence Based Scholars Program was supported by a grant from the Walden and Jean Young Shaw Foundation.
- Vicky R. Bowden, DNSc, RN, Azusa Pacific University, CHOC Children's Hospital EBP Scholars Mentor.
- Jennifer Hayakawa, DNP, PCNS-BC, CNRN, CCRN, Nurse Scientist, CHOC Children's.



Bibliography:

- Bashir, R. A., Callejas, A. M., Osioovich, H. C., & Ting, J. Y. (2016). Percutaneously inserted central catheter-related pleural effusion in a level III neonatal intensive care unit: A 5-year review (2008-2012). *Journal of Parenteral and Enteral Nutrition*, 1-6.
- Baskin, K. M., Jimenez, R. M., Cahill, A. M., Jawad, A. F., & Towbin, R. B. (2008). Cavoatrial junction and central venous anatomy: Implications for central venous access tip position. *Journal of Vascular and Interventional Radiology*, 19(3), 359-365.
- Blackwood, B. P., Kathryn, F. N., Kim, S., & Hunter, C. J. (2015). Peripherally inserted central catheters complicated by vascular erosion in neonates. *Journal of Parenteral and Enteral Nutrition*, 1-5.
- Chided, F., Abbas, A., & Morris, L. (2005). Radiographic inguinal curl may indicate paraspinous misplacement of percutaneously inserted central venous catheters: Report of three cases. *Pediatric Radiology*, 35(7), 684-687.
- Cincinnati Childrens Hospital. (2012). Upper limb PICC tip target position. Retrieved from <https://www.cincinnatichildrens.org/service/v/vascular-access/hcp/>
- Cincinnati Childrens Hospital. (2012). Lower limb PICC tip target position. Retrieved from <https://www.cincinnatichildrens.org/service/v/vascular-access/hcp/>
- Colacchio, K., Deng, Y., Northrup, V., & Bizzarro, M. J. (2012). Complications associated with central and non-central venous catheters in a neonatal intensive care unit. *Journal of Perinatology*, 32(12), 941-946.
- Connolly, B., Mawson, J. B., MacDonald, C. E., Chait, P., & Mikailian, H. (2000). Fluoroscopic landmark for SVC-RA junction for central venous catheter placement in children. *Pediatric Radiology*, 30(10), 692-695.
- Doellman, D., Buckner, J. K., Hudson Garrett, J., Catual, J. P., Frey, A. M., Lamagna, P., Runde, D. A., Schears, G. J. & Whitehead, M. (2015). Best practice guidelines in the care and maintenance of pediatric central venous catheters (2nd ed.). Herriman, UT: Association for Vascular Access.
- Gupta, R., Drendel, A. L., Hoffman, R. G., Quijano, C. V., & Uhing, M. R. (2016). Migration of central venous catheters in neonates: A radiographic assessment. *American Journal of Perinatology*, 33(6), 600-604.
- Hostetter, R., Nakasawa, N., Tompkins, K., & Hill, B. (2010). Precision in central venous catheter tip placement: A review of the literature. *Journal of the Association for Vascular Access*, 15(3), 112-125.
- Infusion Nurses Society. (2011). Infusion therapy standards of practice. *Journal of Infusion Nursing*, 34(15), 1-96.
- Jain, A. & Shah, P. (2013). Peripherally inserted central catheter tip position and risk of associated complications in neonates. *Journal of Perinatology*, 33(4), 307-312.



Mason Wyckoff, M. & Sharp, E. L. (2015). *Peripherally inserted central catheters: Guideline for practice* (3rd ed.). Chicago, IL: National Association of Neonatal Nurses.

Racadio, J. M., Doellman, D. A., Johnson, N. D., Bean, J. A., & Jacobs, B. R. (2001). Pediatric peripherally inserted central catheters: Complication rates related to catheter tip location. *Pediatrics*, 107(2), 1-4.

United States Food & Drug Administration. (1989). Precautions necessary with central venous catheters. *FDA Drug Bulletin*, 19(2), 15-16.

Vesely, T. M. (2003). Central venous catheter tip position: A continuing controversy. *Journal of Vascular and Interventional Radiology*, 14(5), 527-534.