

Evidence Based Recommendation

Peripherally Inserted Central Venous Catheter (PICC)

Optimal Tip Placement & Maintenance

September 2016

Inclusion criteria: Neonatal and pediatric patients with a PICC placement at CHOC Children's Hospital

Exclusion criteria: Exceptions to non-central PICC tip placement would include the rare circumstance when central PICC placement is not possible (i.e. patients with single ventricle physiology when the left lower extremity is not accessible, or patients with limited vascular access as determined by the provider).

Recommendations:

1. The optimal upper limb catheter tip location is the distal superior vena cava (SVC)- lower $\frac{1}{2}$ to $\frac{1}{3}$ of SVC (Baskin et al., 2008; Doellman et al., 2015; Infusion Nurses Society, 2011; Mason Wyckoff & Sharp, 2015; United States Food & Drug Administration, 1989).
 - a. The most reliable radiographic landmark to define the upper and lower boundaries of the SVC is the "Right Tracheobronchial Angle" (Baskin et al., 2008; Connolly et al., 2000; Hostetter et al., 2010; Vesely, 2003).
 - b. Distance from carina to the Cavo-atrial junction is 2.0 vertebral body units \pm 0.4 (Baskin et al., 2008).
 - c. *CHOC Children's Hospital should use 1.5 vertebral units (not to exceed 1.7) as the target zone to guarantee tip placement outside the right atrium. Target triangle: Carina – 1.5 vertebral units – right main bronchus (see upper limb figure).*
2. The optimal lower limb catheter tip location is in the high IVC between T9 - T11 (see lower limb figure) (Mason Wyckoff & Sharp, 2015; Racadio et al., 2001).
 - a. When placing a PICC line in the left lower leg and there is a slight zigzag appearance of the catheter and/or a radiographic inguinal curl occurs, consider obtaining a cross-table, lateral film to exclude paraspinal misplacement (Chedid et al., 2005).
3. A chest X ray to determine appropriate tip placement should be performed:
 - a. Directly after insertion.
 - b. Repeat X ray is required with ≥ 1 cm adjustments in the neonatal and the pediatric population.
 - c. Post PICC insertion follow-up X ray within 12-24 hours of insertion to be done next morning (0600-0800) (Gupta et al., 2016; Mason Wyckoff & Sharp, 2015).
 - d. Every 2 weeks to assess for migration.
 - e. When an X ray is obtained for any purpose where PICC tip may be visualized, the radiographic analysis should always include a description of tip location.
 - f. For upper extremity PICC placement: Ensure patient is supine, both arms are adducted, and head midline.
 - g. For lower extremity PICC placement: Ensure patient is supine, legs are in neutral adducted position (slightly bent).

4. For the patients with the following single ventricle physiology:
 - Atrial atresia
 - Mitral atresia
 - Pulmonary atresia
 - Tricuspid atresia
 - Unbalanced AV canal
 - Hypoplastic left heart syndrome
 - Cardiac heterotaxy defects
 - a. Use the smallest catheter to complete the therapeutic goal (generally 3Fr PICC line is used to obtain laboratory samples and give blood products).
 - b. Place PICC line in lower extremities, preferably left leg. Right leg is used for heart catheterization.
 - c. If there are issues or questions consult with cardiothoracic surgeon.
5. Discuss all non-central/malpositioned PICC tips with the attending physician.

Rationale and Support Information:

1. Central tip locations are superior vena cava (SVC), cavo-atrial junction and inferior vena cava (IVC). Rationales for placement in these vessels include: increased venous diameter with an increased blood flow, the infusate is rapidly diluted, and the physiologic flow dynamics maintains the catheter parallel to vessel wall with a decreased catheter tip contact with vein wall (Colacchio et al., 2012; Racadio et al., 2001).
2. Non-central tip locations include placement in subclavian vein, axillary vein and brachiocephalic vein. The rationale to not use these vessels include: decreased venous diameter causing a decreased blood flow that can lead to increased catheter tip contact with the vein wall. This results in injury to tunica intima that activates the clotting process leading to increased risk for thrombophlebitis, thrombosis & infection (Colacchio et al., 2012; Jain et al., 2013; Racadio et al., 2001).
3. Radiographic Landmarks and Optimal Tip Location:
 - a. The optimal catheter tip location is the distal superior vena cava (SVC)- lower $\frac{1}{2}$ to $\frac{1}{3}$ of SVC (Baskin et al., 2008; Doellman et al., 2015; Infusion Nurses Society, 2011; Mason Wyckoff & Sharp, 2015; United States Food & Drug Administration, 1989).
 - b. The most reliable radiographic landmark to define the upper and lower boundaries of the SVC is the “Right Tracheobronchial Angle” (Baskin et al., 2008; Connolly et al., 2000; Hostetter et al., 2010; Vesely, 2003).
 - c. Distance from carina to the Cavo-atrial junction is 2.0 vertebral body units \pm 0.4 (Baskin et al., 2008).
 - d. *CHOC Childrens Hospital should use 1.5 vertebral units (not to exceed 1.7) as the target zone to guarantee tip placement outside the right atrium. Target triangle: Carina – 1.5 vertebral units – right main bronchus (see upper limb figure).*
 - e. The optimal lower limb catheter tip location is in the high IVC between T9 - T11 (see lower limb figure). This is based on vessel diameter, highest venous blood flow, and physiologic flow dynamics (Mason Wyckoff & Sharp, 2015; Racadio et al., 2001).
 1. When placing a PICC line in the left lower leg and there is a slight zigzag appearance of the catheter and/or a radiographic inguinal curl occurs,

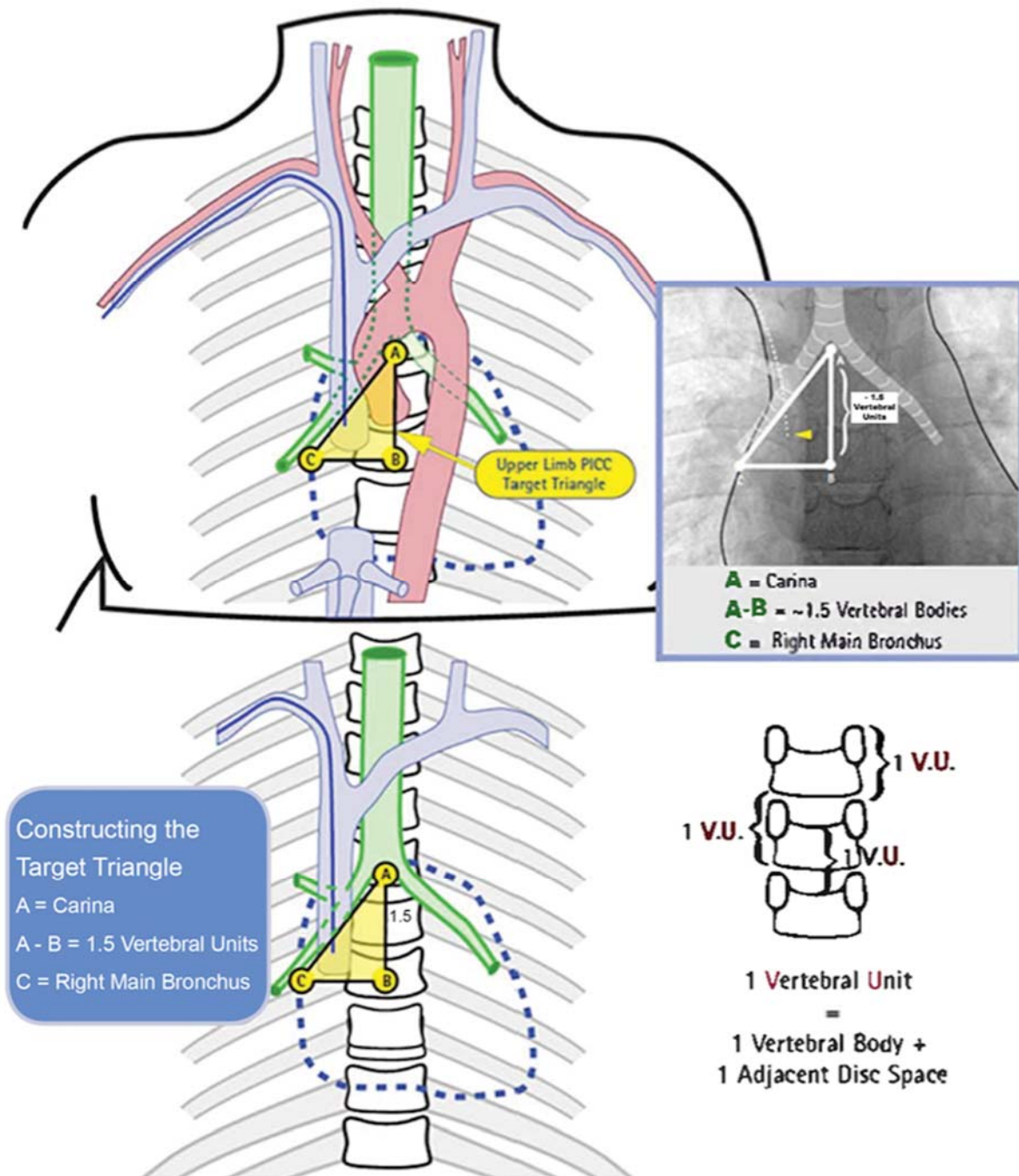
consider obtaining a cross-table, lateral film to exclude paraspinal misplacement. Paraspinal misplacement of a PICC line can cause serious complications with increased morbidity (Chedid et al., 2005).

4. Schedule for X ray analysis and placement verification:
 - a. X ray verification is required to verify initial placement of the catheter tip.
 - b. Catheter migration occurs at a higher percentage within the first 24 hours of catheter placement; therefore serial radiographic assessment of catheter tip location is needed to avoid catheter complications including associated pericardial effusion (Blackwood et al., 2015; Bashir et al., 2016; Gupta et al., 2016).
 - c. When an X ray is obtained for any purpose where PICC tip may be visualized, the radiographic analysis should always include a description of tip location.
 - d. On all patients, growth changes including weight loss/gain may impact tip placement. Therefore, radiography needs to be completed a minimum of every two weeks to assess tip placement.

Figures:

Upper Limb PICC Target Zone

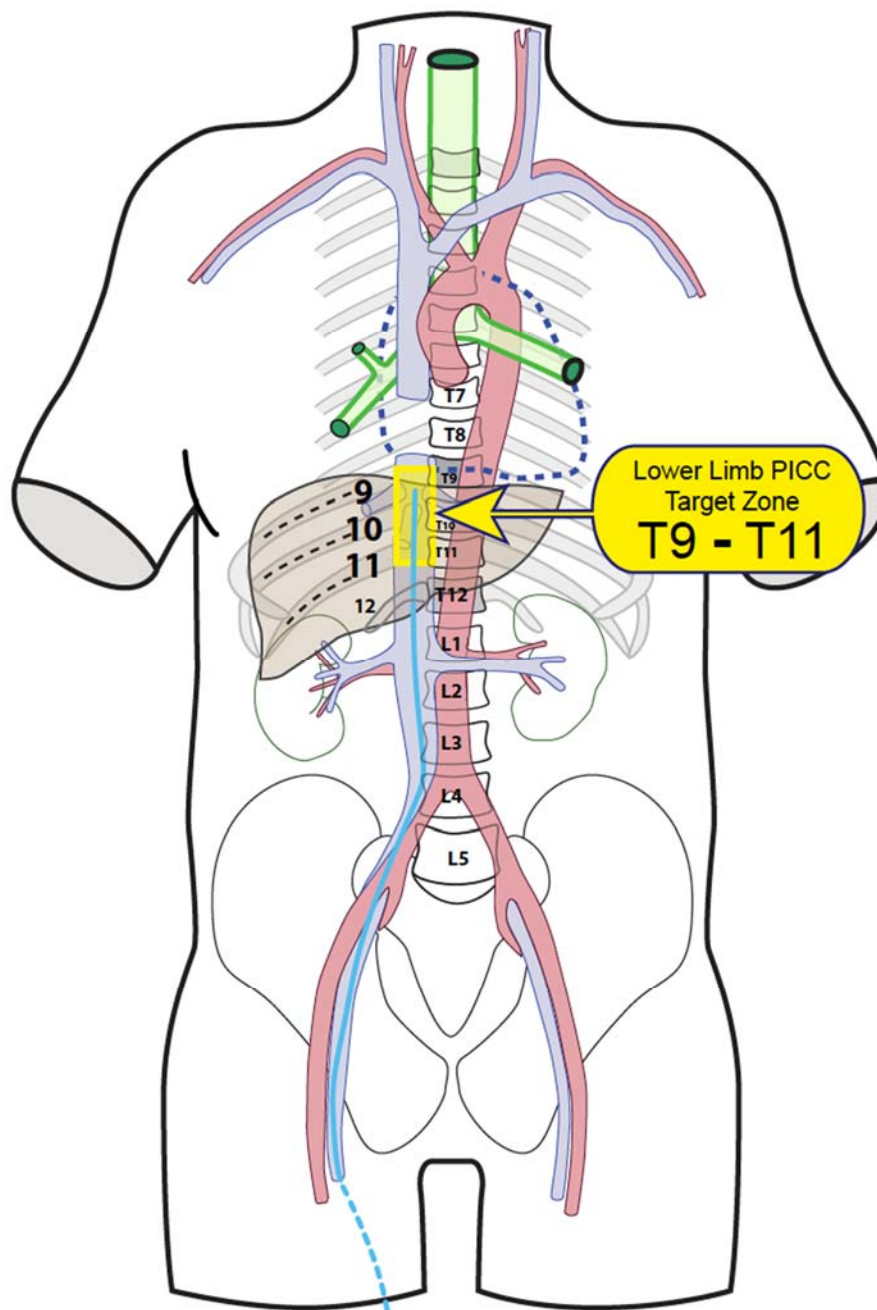
CHOC Children's Hospital's target zone is 1.5 vertebral units not to exceed 1.7.



(Figure modified from Cincinnati Children's Hospital, 2012)

Lower Limb PICC Tip Target Zone:

CHOC Children's Hospital's target zone is T9-T11.



(Cincinnati Children's Hospital, 2012)

Stakeholder group review:

Dr. Nathan Holmes, Radiologist
Dr. Joanne Starr, Cardio-Thoracic Surgeon
Dr. Juliette Hunt, Critical Care Intensivist
Dr. Irfan Ahmad, Neonatologist

Author: P. Fridolfsson, BSN, RNC-NIC, VA-BC.

References

- Bashir, R. A., Callejas, A. M., Osiovich, H. C., & Ting, J. Y. (2016). Percutaneously inserted central catheter-related pleural effusion in a level III neonatal intensive care unit: A 5-year review (2008-2012). *Journal of Parenteral and Enteral Nutrition*, 1-6.
- Baskin, K. M., Jimenez, R. M., Cahill, A. M., Jawad, A. F., & Towbin, R. B. (2008). Cavoatrial junction and central venous anatomy: Implications for central venous access tip position. *Journal of Vascular and Interventional Radiology*, 19(3), 359-365.
- Blackwood, B. P., Kathryn, F. N., Kim, S., & Hunter, C. J. (2015). Peripherally inserted central catheters complicated by vascular erosion in neonates. *Journal of Parenteral and Enteral Nutrition*, 1-5.
- Chided, F., Abbas, A., & Morris, L. (2005). Radiographic inguinal curl may indicate paraspinal misplacement of percutaneously inserted central venous catheters: Report of three cases. *Pediatric Radiology*, 35(7), 684-687.
- Cincinnati Childrens Hospital. (2012). *Upper limb PICC tip target position*. Retrieved from <https://www.cincinnatichildrens.org/service/v/vascular-access/hcp/>
- Cincinnati Childrens Hospital. (2012). *Lower limb PICC tip target position*. Retrieved from <https://www.cincinnatichildrens.org/service/v/vascular-access/hcp/>
- Colacchio, K., Deng, Y., Northrup, V., & Bizzarro, M. J. (2012). Complications associated with central and non-central venous catheters in a neonatal intensive care unit. *Journal of Perinatology*, 32(12), 941-946.
- Connolly, B., Mawson, J. B., MacDonald, C. E., Chait, P., & Mikailian, H. (2000). Fluoroscopic landmark for SVC-RA junction for central venous catheter placement in children. *Pediatric Radiology*, 30(10), 692-695.
- Doellman, D., Buckner, J. K., Hudson Garrett, J., Catual, J. P., Frey, A. M., Lamagna, P., Runde, D. A., Schears, G. J. & Whitehead, M. (2015). *Best practice guidelines in the care and maintenance of pediatric central venous catheters* (2nd ed.). Herriman, UT: Association for Vascular Access.
- Gupta, R., Drendel, A. L., Hoffman, R. G., Quijano, C. V., & Uhing, M. R. (2016). Migration of central venous catheters in neonates: A radiographic assessment. *American Journal of Perinatology*, 33(6), 600-604.
- Hostetter, R., Nakasawa, N., Tompkins, K., & Hill, B. (2010). Precision in central venous catheter tip placement: A review of the literature. *Journal of the Association for Vascular Access*, 15(3), 112-125.

- Infusion Nurses Society. (2011). Infusion therapy standards of practice. *Journal of Infusion Nursing*, 34(15), 1-96.
- Jain, A., & Shah, P. (2013). Peripherally inserted central catheter tip position and risk of associated complications in neonates. *Journal of Perinatology*, 33(4), 307-312.
- Mason Wyckoff, M., & Sharp, E. L. (2015). *Peripherally inserted central catheters: Guideline for practice* (3rd ed.). Chicago, IL: National Association of Neonatal Nurses.
- Racadio, J. M., Doellman, D. A., Johnson, N. D., Bean, J. A., & Jacobs, B. R. (2001). Pediatric peripherally inserted central catheters: Complication rates related to catheter tip location. *Pediatrics*, 107(2), 1-4.
- United States Food & Drug Administration. (1989). Precautions necessary with central venous catheters. *FDA Drug Bulletin*, 19(2), 15-16.
- Vesely, T. M. (2003). Central venous catheter tip position: A continuing controversy. *Journal of Vascular and Interventional Radiology*, 14(5), 527-534.